



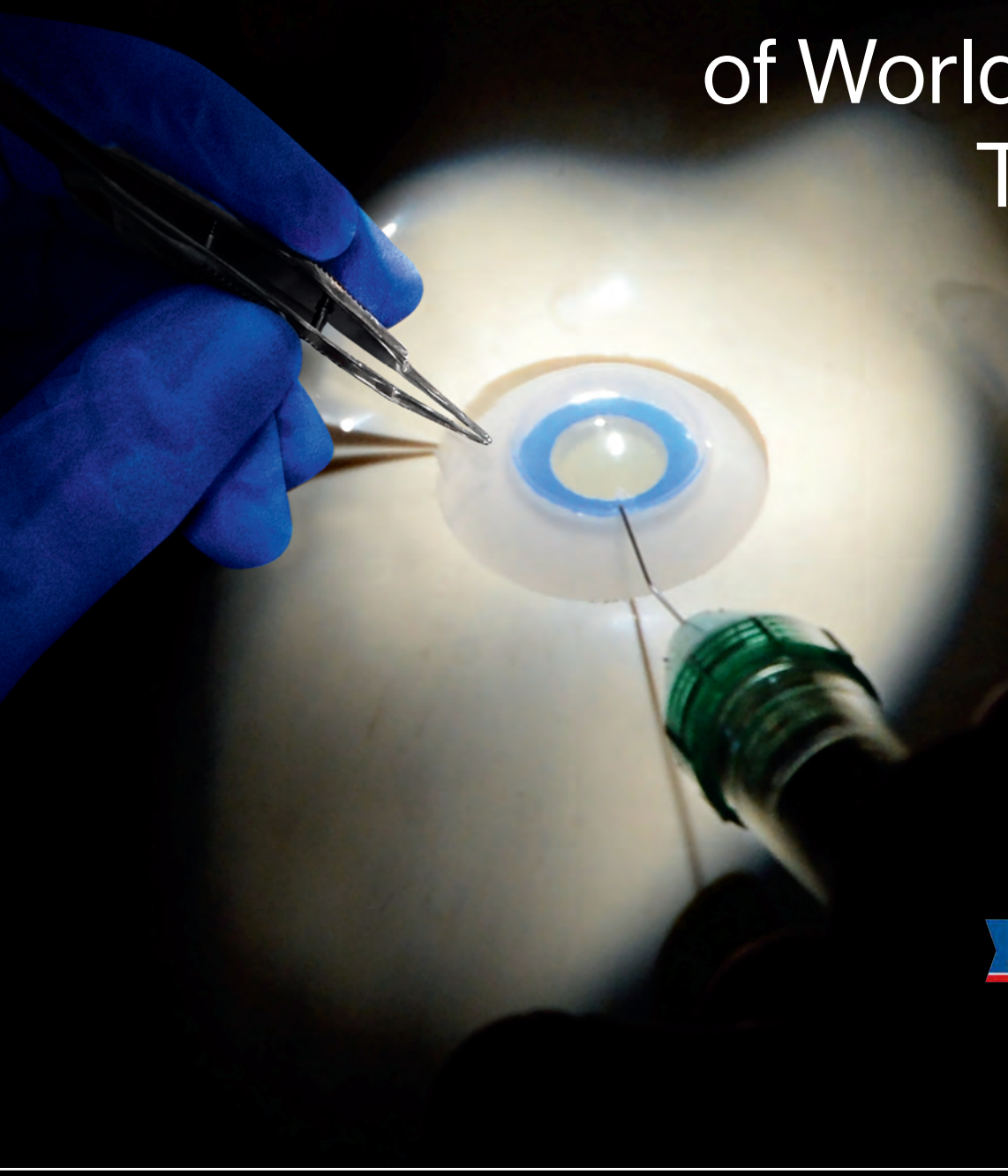
New York  
Eye and Ear  
Infirmary of  
Mount  
Sinai

SPECIALTY REPORT | FALL 2019

# Department of Ophthalmology

[www.NYEE.edu](http://www.NYEE.edu)

Building on a  
Legacy  
of World-Class  
Training



# In Search of Lost Infirmary

# Histories

By Richard B. Rosen, MD

When I first came to the New York Eye and Ear Infirmary in 1984 as a medical student, a second-year resident, Scott Spector, MD, regaled me with stories of the Infirmary past—how the legendary architect Stanford White supposedly helped design the South Building, how Francis Ford Coppola and his crew took over a ward on the fourth floor of the Infirmary's



Official seal of NYEE, unveiled in 1824

South Building to shoot the hospital interiors for *The Godfather*, and how the founding hospital president was a signer of the U.S. Constitution. It was not until a few years later, when our new department chair, Joseph Walsh, MD, returned from his fellowship-turned-chairmanship at Montefiore Medical Center/Albert Einstein College of Medicine to take the helm, that I began to learn the great legacy of the Infirmary and its place in American ophthalmology.

Dr. Walsh was an enthusiastic student of history, incessantly scavenging for scraps of our past and cobbling them into an ever-expanding compilation of lost anecdotes. He collected and identified classes of bygone residents, dove into old collections of photographs, and perused ancient Board of Trustees reports. He formalized the department annual reports, creating them on his desktop computer, and initially assembling them in Duo-Tang folders printed at the sixth floor print shop. Slowly, I was seduced into the richness of this dusty trove of documents and references from days past.

Given my own previous career in photography, I was inspired to illustrate his reports with photos from our embryonic Advanced Retinal Imaging Center, Dr. Robert Ritch's Ocular Imaging Center, and Dr. Steven McCormick's invigorated Pathology Laboratory. The reports slowly expanded into published volumes with striking color images. From time to time, alumni, staff members, and even

patients would contribute photos and memorabilia, further stoking the flames of nostalgia and reverence for the rich traditions built by our forebears. Oral histories from the likes of Drs. Seymour Fradin, Thomas Muldoon, Richard S. Koplin, and others, as well as contributions from our development and external affairs directors, Ann Brancato and Jean Thomas, helped fill in the many gaps from the nearly 200 years since the founders' initial dream.

Our infancy was marked by a modest beginning and an adolescent period of rapid growth, which featured frequent moves to new homes as we outgrew our digs every few years, before finally planting ourselves firmly on Second Avenue at 13th Street. From this point on, we began to acquire the trappings of an adult organization with sustained expansion as we hustled to keep up with a growing following of New Yorkers who recognized the gem in their midst.

Within a few years, many of our physicians also began to export our brand of expertise and helped pass it on to new institutions and departments of ophthalmology locally, nationally, and internationally,



Founder, Dr. Edward Delafield



The Infirmary's permanent home on the corner of Second Avenue and 13th Street, 1856



Founder, Dr. John Kearny Rodgers

sharing the culture of caring and curing that they had learned here. New advances in anesthesia, surgical techniques, and clinical expertise to enhance patient care, and academic associations such as the American Ophthalmological Society, the New York Ophthalmological Society, and later, ARVO and the Pan American Ophthalmology Association, were pioneered by our faculty. Quietly, we remained steadfast to our mission of service as the first and ultimately last freestanding eye institute in the country.

With the approach of our bicentennial, Dr. Walsh encouraged me to assemble a historical scrapbook of our place in American history. Further emboldened by some fellow history aficionados, including Drs. Jay M. Galst, Stanley B. Burns, and James G. Ravin, I serendipitously stumbled upon Laurie Levin, a author-anthropologist and chronicler of institutional histories,

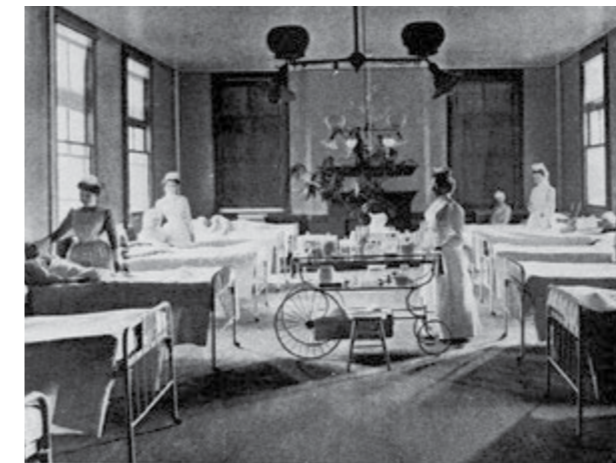
and her creative partner, Larry Zempel, graphic artist extraordinaire, who agreed to help me compose and assemble a modern history and family album of the Infirmary.

Sadly, Dr. Walsh passed away in 2017, never seeing the fruition of our shared aspiration. To honor his vision and inspiration, I have dedicated the book to his memory, for his mentorship and friendship, and for exemplifying the ideals of compassionate care, boundless curiosity, and leadership. This book also honors the thousands of men and women of the Infirmary over the past 200 years who have dedicated their lives to repair and enhance the lives of so many grateful patients.

In the spring of 2020, we look forward to sharing this lusciously illustrated family volume of stories and facts, highlighting our first 200 years.



Illustration of the Infirmary published in Frank Leslie's Illustrated Newspaper, 1875



Patient ward, Schermerhorn Pavilion, 1880s



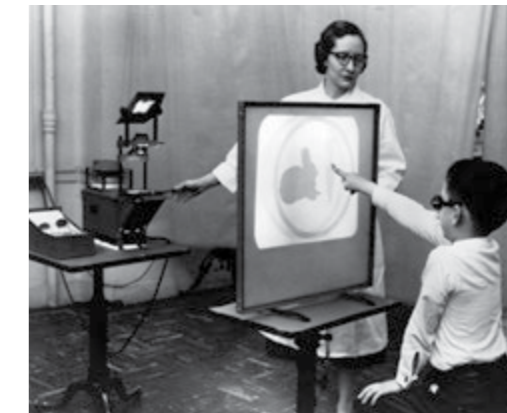Surgery in progress, 1940s



Thomas Muldoon, MD, Chief of Retina Service, 1995-2011



Roof garden and the David W. Look Sun Parlor for fresh air treatments, 1900s



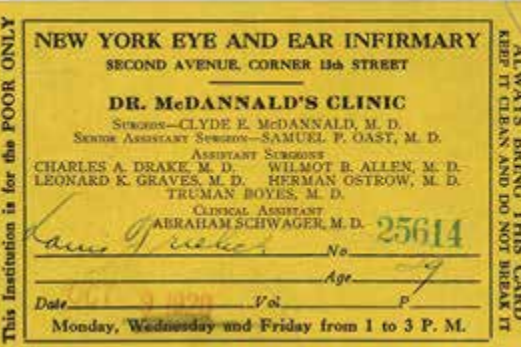
Amblyopia treatment, 1930s



Eikonometer, 1930s (the only one in NYC)



Pathological Department, 1900s



Patient appointment card, 1929



Wooden chair with NYEE seal given to graduating residents since 1972



(Top) Rendering of the new downtown campus, northeast view from corner of 2nd Avenue  
 (Right) Rendering of the new downtown campus, view of the main entrance on 14th Street



# Honoring Our Past. Envisioning Our Future.

2019 is ushering in a new era for New York Eye and Ear Infirmary of Mount Sinai (NYEE). Mount Sinai's June announcement about the \$1 billion commitment to rebuild, renew, and revitalize health care for the Downtown community will have a transformative effect on patient care. And NYEE will greatly benefit from the new, integrated campus, resulting in a stronger, more vibrant NYEE—able to better care for the hospital's patients, to train the next generations of physicians, and to advance research and innovation.

The plans for the Downtown campus include modernization and enhancement of services at NYEE, construction of the new Mount Sinai Beth Israel Hospital (MSBI), and the creation of a new Mount Sinai Comprehensive Behavioral Health Center on Rivington Street. Together, these steps represent a leap forward in the transformation of care for patients, adapting the health system to the changing health care landscape, and revolutionizing the delivery of care.

The new MSBI facility will be built on 13th

Street and physically joined with NYEE's North and South buildings, integrating both facilities into one unified campus. An essential part of this integration is ensuring that both hospitals will retain their own individual and distinct identities. "Strengthening NYEE's longstanding and valued brand and reputation as a leader in specialty care nationally and internationally remains a vital part of our mission and vision for NYEE," affirms James C. Tsai, MD, President of NYEE. "Our new approach to how we deliver care, builds upon the strengths of two historic hospitals while maintaining the unique brand identity we have fostered for almost two centuries."

The integration of the hospitals will allow the implementation of significant operational efficiencies for both MSBI and NYEE, but most importantly, it will allow for the investment in and expansion of clinical services for NYEE's patients, including a revitalized and upgraded hospital eye trauma program that would be available around the clock for emergency eye care. In addition, the proximity to enhanced state-of-the-art imaging, pharmacy and

laboratory services, and on-campus critical care support, will give NYEE the ability to safely treat more complex conditions and patients.

The NYEE campus will receive long-overdue renovations as well as the planned opening of a brand new Ambulatory Surgery Center. NYEE will also transition to the EPIC electronic medical record system, improving the hospital's ability to care for patients and monitor their long-term well-being, promoting better outcomes, and ensuring enhanced operational efficiency.

"For nearly 200 years, NYEE has been the preeminent leader in eye care, education, and vision research. Our integration with MSBI marks a new and important next step in the history and future of NYEE," explains Paul A. Sidoti, MD, Site Chair, Department of Ophthalmology at NYEE. "By leveraging services, expertise, and technology available at the new MSBI and across the Mount Sinai Downtown network, NYEE will become deeper, stronger, and better positioned to serve our community for decades to come."

# C O N T E N T S

2. Message From Department of Ophthalmology Leadership
4. Enhancing Our Reputation for World-Class Training
6. Getting Back on Track: A String of Complex Surgeries Takes Patient From Near-Blindness to Active Life
8. Rich Data Sets Are Fueling the Move to AI
9. Ushering in a New Era of Unlimited Potential With the First Robot in the U.S. for Precision Ophthalmic Surgery
10. Ophthalmic Pathology Referral Service Is Filling a Need on a National Scale
11. New Retinal Capillary Density Mapping Technique Could Provide an Advanced Window on Disease
12. Taking Retinal Imaging to the Cellular Level
13. After-Hours OCT Could Be a Sight Saver for Some Patients
14. NYEE Team Saves Eyesight in Toddler With Aggressive Cystic Epithelial Downgrowth
15. A New Supplement 'Cocktail' Shows Promise in the Fight Against Glaucoma
16. Seeing Glaucoma in a New Light
18. Unraveling the Clinical Mystery of a Rare Tumor
20. Retinal Vein Occlusion Now Provides a Window Into the Heart
21. Department of Ophthalmology at a Glance
22. Faculty News



# Message From Department of Ophthalmology Leadership Icahn School of Medicine at Mount Sinai Mount Sinai Health System

On the eve of our 2020 bicentennial, we are more committed than ever to building upon the rich history and tradition of New York Eye and Ear Infirmary of Mount Sinai (NYEE) as America's first specialty hospital. Our ongoing integration and collaboration with the Mount Sinai Health System—a leading health care enterprise with \$8 billion a year in revenue, 7,200 physicians, and a globally recognized research capability—will ensure that we maintain our role as a premier center for ophthalmic clinical care, research, and education as we embark on our third century.

We are proud to highlight the considerable progress we have made over the past year. In the field of education, we announced the integration of the NYEE and The Mount Sinai Hospital (MSH) ophthalmology residency training programs. NYEE will anchor the combined program, building upon its longstanding reputation as a leader in ophthalmic education, and its ranking in the top 20 residency programs nationally by 2019-2020 Doximity Residency Navigator. This initiative represents a new era for NYEE and Mount Sinai because the newly ACGME-accredited three-year residency program will be the largest in the nation, with 30 positions total.

The trainees will benefit from increased diversity of resident experiences, as the network of training sites grows beyond NYEE and MSH to include Elmhurst Hospital in New York City's borough of Queens and the James J. Peters VA Medical Center in the Bronx, giving trainees the chance to treat the widest spectrum of rare and complex eye disorders within a diverse array of health care facilities. Furthermore, graduating medical students who match into the combined residency program will participate in an integrated internship year where they will spend three months rotating through ophthalmology, in addition to nine months spent in medicine (including elective rotations pertinent to ophthalmology), prior to starting their residency. This is an exciting time for both faculty and trainees, and it brings us closer to our goal of becoming one of the top 10 ophthalmology residency programs in the nation.

We also broadened our education platform in 2019 by welcoming our first pediatric ophthalmology fellow. This joint program with MSH will not only round out the nationally recognized fellowship training of both institutions, but also improve the quality of clinical care we're able to deliver to children with complex eye disorders, as well as adults with strabismus.

Clinical excellence for patients of all ages, and from all parts of the community, continues to be the centerpiece of what we do at NYEE. In line with that mission, plans are underway for an ambulatory surgery center (ASC) in downtown Manhattan, which will give patients convenient access to advanced, efficient ophthalmic procedures outside the hospital setting. The ASC will be a partnership between NYEE and voluntary physicians, continuing a vital relationship that has been a hallmark of our institution for almost two centuries.

Clinical excellence also includes the ability to offer unique professional services that cannot be accessed at most other institutions. Here, NYEE has clearly taken the lead with our new Pathology and Laboratory Medicine Referral Service, staffed with a team of three highly skilled ophthalmic-focused clinical pathologists. This program will meet the round-the-clock, often urgent needs of ophthalmologists, surgical centers, and hospitals across the tri-state area—and, eventually, the nation—for quick and accurate biopsy, microbiology, polymerase chain reaction, and cytology test results on ophthalmic samples. We are excited by the opportunity to increase our outreach and offer highly specialized services to



**James C. Tsai, MD, MBA**  
President, New York Eye and Ear Infirmary of Mount Sinai  
System Chair, Department of Ophthalmology  
Mount Sinai Health System



**Paul A. Sidoti, MD**  
Site Chair, Department of Ophthalmology  
New York Eye and Ear Infirmary of Mount Sinai




**Louis R. Pasquale, MD, FARVO**  
Site Chair, Department of Ophthalmology  
The Mount Sinai Hospital and Mount Sinai Queens

a broader range of clinicians not only in the New York region, but also nationally.

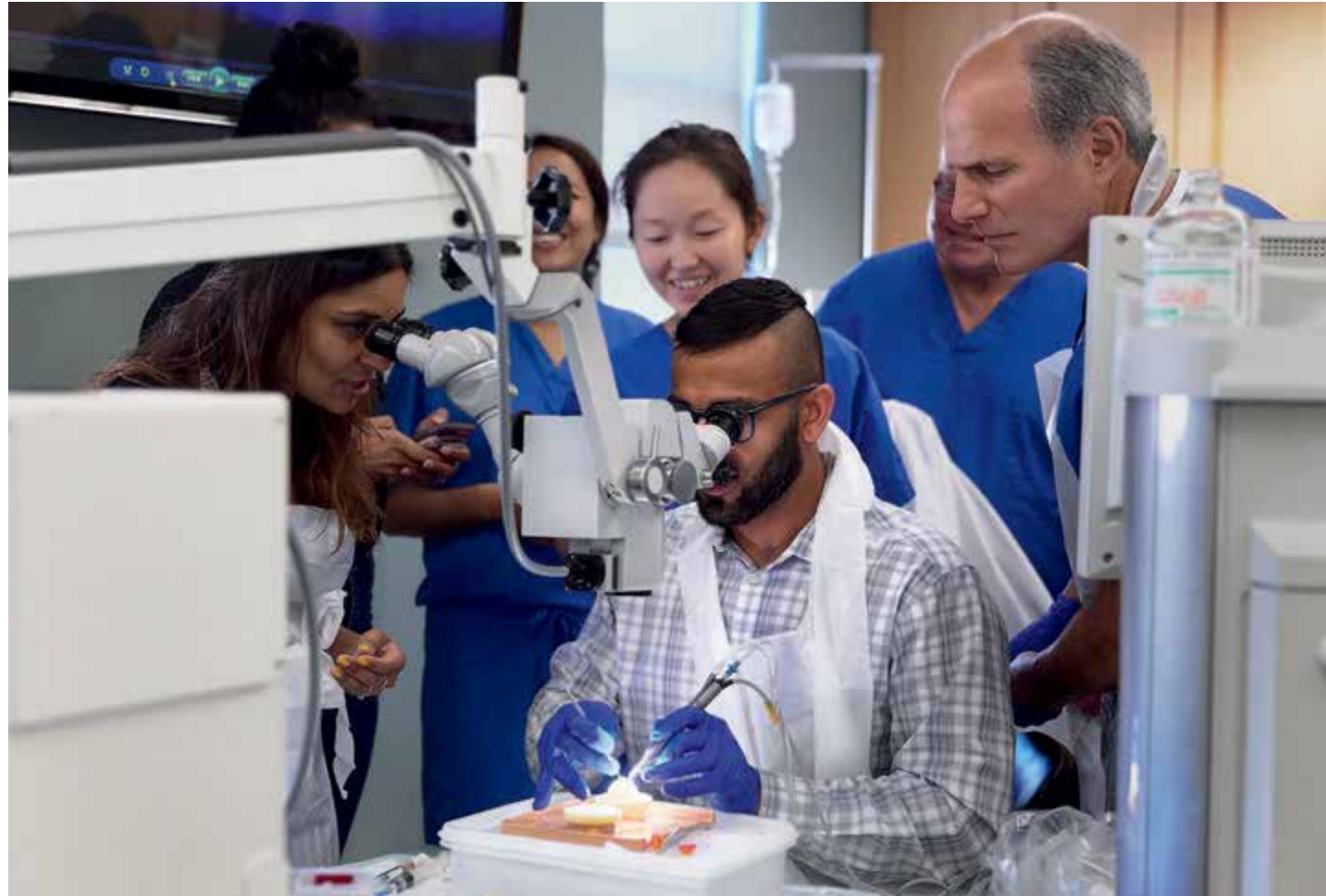As we look to write the next chapter in our storied history of growth and achievement, no part will be more crucial than research and innovation. We are excited that we are now a part of Mount Sinai's cutting-edge research network, and are able to tap into resources that include one of the world's largest biobank repositories to use the power of genomics and big data to elevate medical decision-making, and optimize the customization of health care. We will continue to leverage our own advanced clinical research facilities and the Mount Sinai/NYEE Eye and Vision Research Institute to translate technologies like telemedicine, adaptive optics, gene

transfer therapy, and artificial intelligence into practical applications that will move the field of ophthalmology forward. We will soon take the lead in another important arena by becoming the first institution in the United States to introduce a robotic microsurgical intervention system for complex ocular surgery.

Having spent the last 200 years delivering world-class clinical care and advancing ophthalmology through superlative clinical research and educational programs, we are well aware of our priorities for the future. Foremost among them is refusing to allow ourselves to rest until we have developed breakthrough treatments for a multitude of eye diseases that can significantly improve quality of life for our patients.



# Enhancing Our Reputation For World-Class Training



By recognizing the pivotal role of training in creating the next generation of ophthalmologists, New York Eye and Ear Infirmary of Mount Sinai (NYEE) has put itself on the cusp of becoming one of the nation's top 10 residency programs. Already a top-20 leader in ophthalmic education, NYEE is leveraging its integration with The Mount Sinai Hospital (MSH) to create not just the largest ACGME-accredited program—growing to 30 residents over the next few years—but one of the most advanced, thanks to a challenging curriculum and microsurgical laboratory offering state-of-the-art simulation training.

“Combining the resources and faculties of two major teaching centers brings us to a new level of excellence in terms of what we can provide our residents and fellows,” says Douglas

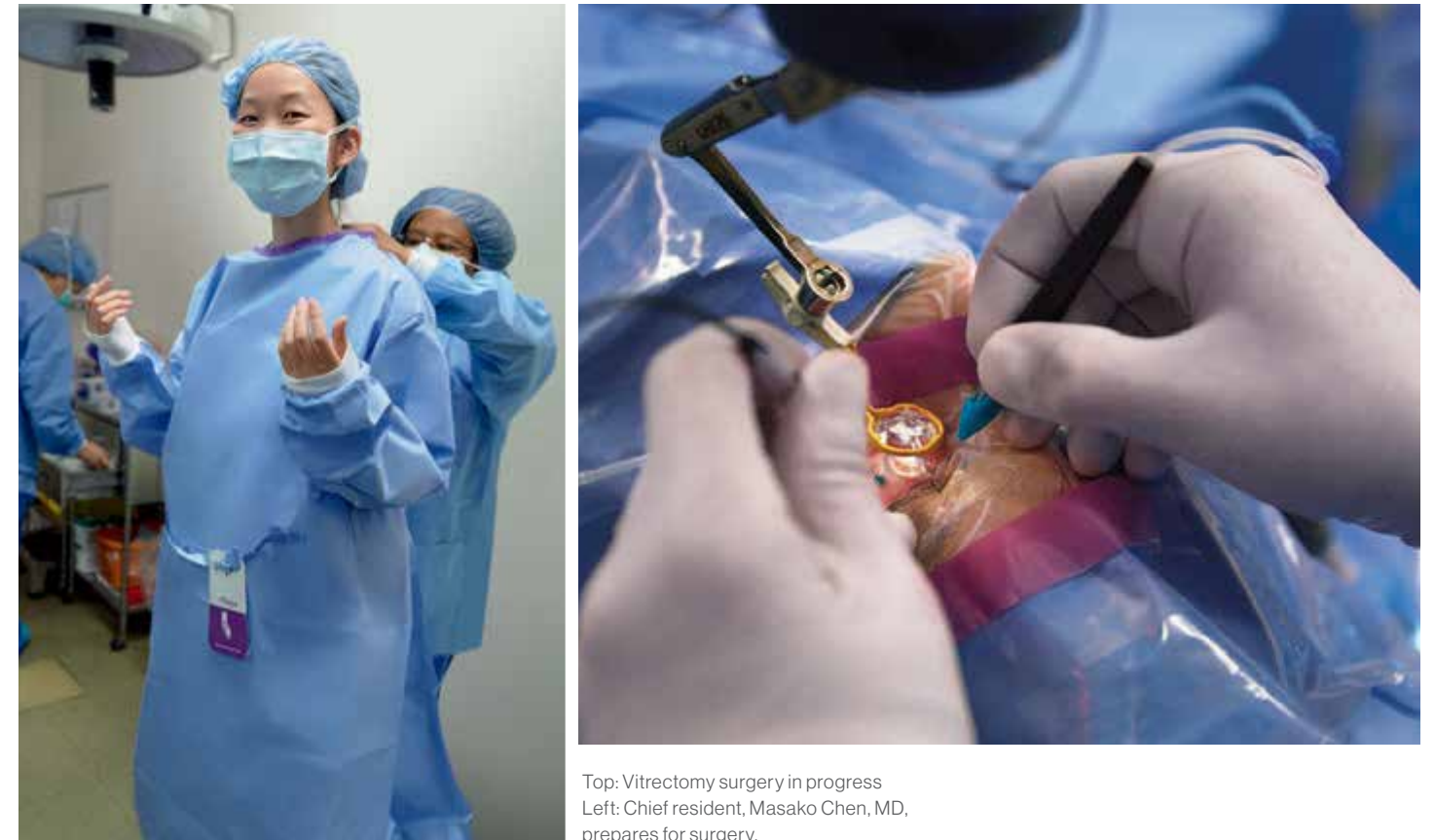
Fredrick, MD, Deputy Chair for Education in the Department of Ophthalmology and Chief of Pediatric Ophthalmology for the Mount Sinai Health System. “Because trainees are exposed to a diverse and challenging range of patients across four distinct health care settings, they get the kind of clinical and operating room experience few other programs across the country are able to offer.”

That thought is reinforced by Harsha S. Reddy, MD, the new Director of Residency Training at NYEE, citing as an example the addition of the James J. Peters VA Medical Center in the Bronx and Elmhurst Hospital in Queens to the rotation of trainees. “We’re committed to world-class ophthalmic training to ensure that excellent surgeons and clinicians emerge from our program,” he says. “Part of our strategy is

Phacoemulsification wet lab at the Jorge N. Buxton, MD, Microsurgical Education Center at NYEE taught by faculty and voluntary physicians.

to expand the diversity of training sites beyond NYEE’s downtown campus and MSH to help physicians-in-training sharpen their knowledge and surgical/clinical skills through a vast range of ocular trauma cases, diverse pathologies, age groups, and instructors who include some of the most skilled and knowledgeable specialists and subspecialists in the field of ophthalmology.”

A unique addition to the residency training program is a joint internship year that will begin next July. Prior to starting their three-year residency, trainees will be enrolled in a one-year internship at a Mount Sinai internal



Top: Vitrectomy surgery in progress  
Left: Chief resident, Masako Chen, MD, prepares for surgery.

medicine program that will include nine months of general medicine and three months of ophthalmology training. “Those three months in ophthalmology will give trainees a significant head start when they begin their residency,” says Dr. Reddy. “They’ll be better prepared to transition not only to patient care, but also to meaningful research projects.”

Residents will continue to benefit in another vital way: the hands-on instruction they get at the Jorge N. Buxton, MD, Microsurgical Education Center, one of the most advanced ophthalmic surgical training sites in the country. Named after the world-renowned corneal surgeon who practiced and taught at NYEE for more than four decades, this fully equipped wet lab has 16 workstations, each with microscopes, microsurgical instruments, synthetic eye models, and simulators for immersive learning of critical surgical steps. “Training good surgeons is such an important part of what we do at NYEE,” emphasizes Tania Tai, MD, Assistant Professor of Ophthalmology and Director of Microsurgical Training at NYEE. “And our wet lab gives residents a running start in learning the complex motor skills and hand-eye coordination they can then take into the operating room.”

The lab’s surgical simulator is particularly important to mastering technique and basic

skills. A cataract surgery module, for example, allows ophthalmologists-in-training to practice capsulorhexis, phacoemulsification, irrigation/aspiration, intraocular lens insertion, and complications management. “By the time our residents join an attending in the OR during their second year of training, they are familiar with every facet of cataract surgery, including the instruments, the flow of the case, and possible complications,” explains Kira Manuasis, MD, Assistant Professor of Ophthalmology and Co-Director of the Cataract Services at NYEE.

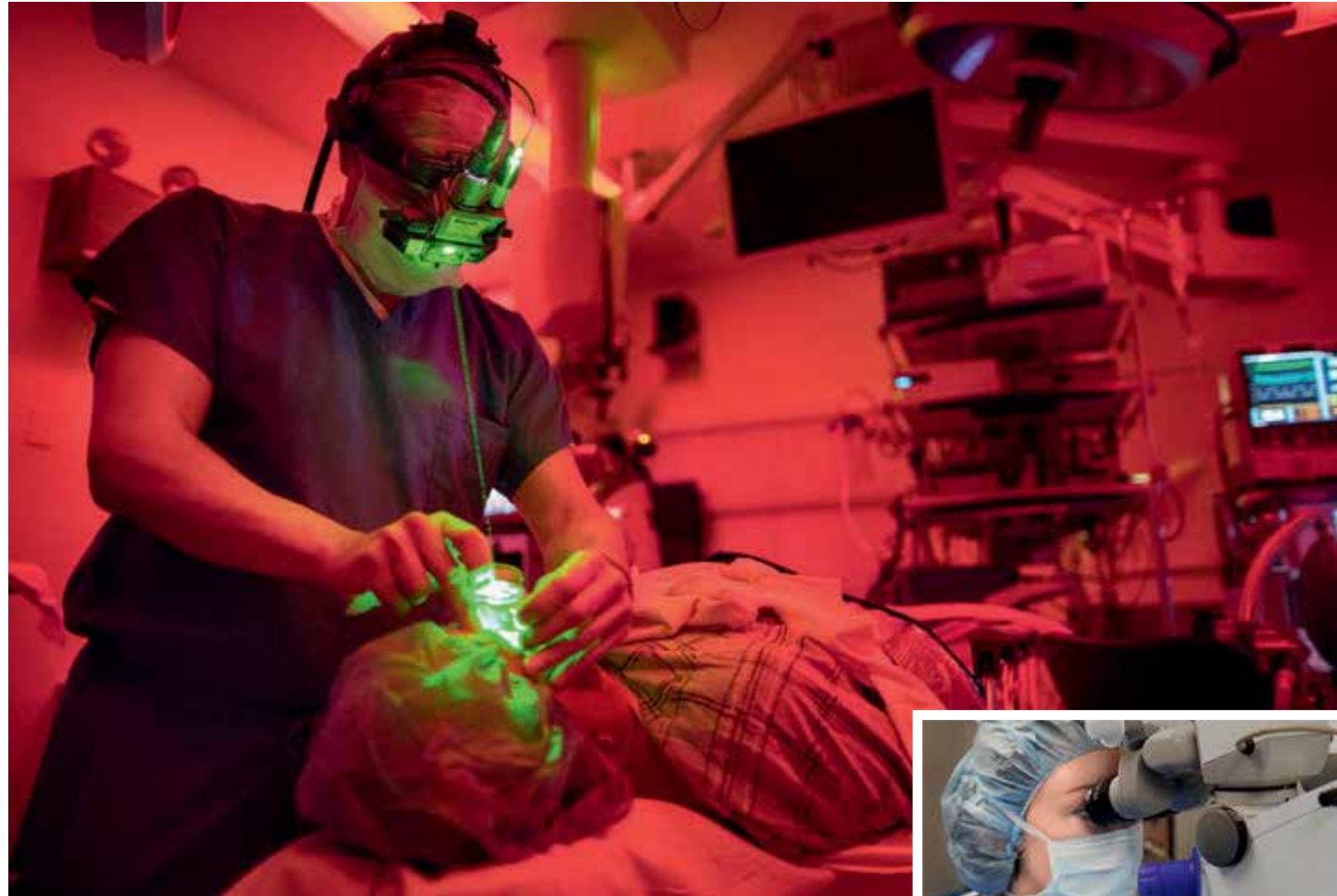Dr. Reddy envisions even greater uses of technology in resident training by expanding the videotaping of surgical cases and building a formal curriculum around a methodical review of these cases by students and their instructors. The combination of a diverse case mix, the state-of-the-art surgical and research facilities of a major academic medical center, and a dedicated full-time and voluntary faculty committed to the education of young ophthalmologists will ensure that NYEE remains a leading institution for the delivery of ophthalmic care and innovation into the next century.

NYEE has further expanded its educational and clinical footprint with the start, this year, of a new pediatric ophthalmology fellowship. This year-long program, accredited by

the Association of University Professors of Ophthalmology Fellowship Compliance Committee, is expected to grow from one fellow the first year to three over the next several years. The fellows, who will be actively involved in training residents, are a vital part of NYEE’s plans to grow its pediatric ophthalmology center of excellence, offering care for everything from basic to the most complex eye disorders in children.

NYEE is burnishing its education credentials in several other visible ways. One is through its active postgraduate continuing education program for ophthalmologists in the tri-state area who want to sharpen their surgical skills and knowledge. This program, known as Transformational Ophthalmology, continues to grow by bringing in renowned experts to NYEE to teach new techniques and modalities that physicians can then integrate into their practices. Another way is through the hospital’s expanding program in global health, a joint effort with Mount Sinai and its Icahn School of Medicine Division of Public Health. Explains Dr. Fredrick: “Whether it’s sending our faculty members to emerging nations to serve as teachers, or our residents and fellows to provide badly needed care, we regard global involvement as inseparable from our commitment to become a premier teaching institution in the United States.”

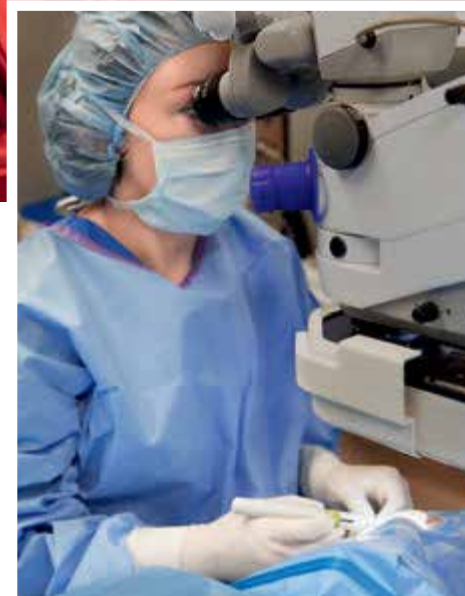# Getting Back on Track: A String Of Complex Surgeries Takes Patient From Near-Blindness to Active Life



By age 36, John Cunningham already had a long history of eye problems. His left eye registered light perception only, as a result of a dense cataract and two retinal detachments at ages 17 and 26. Despite this setback, Mr. Cunningham refused to stay still; the support of his family and one of his favorite activities, playing basketball, helped him cope with his limited vision. But in late 2017, a severely detached retina in his right eye forced him to abandon a Caribbean cruise with his family at mid-point—turning his world upside down. Now, with his right eye reduced to the perception of hand motions only, the sports-loving Mr. Cunningham was forced in the prime of his life to ponder a future without sight.

That he was able a year and a half later to resume an active life, his vision restored, speaks volumes about not just his resolve, but also the skills and determination of his team of surgeons at New York Eye and Ear Infirmary of Mount Sinai (NYEE)—a team that is often called on by other institutions and physicians to apply their expertise with advanced surgical and micro-interventional procedures to the treatment of complex cases.

Helping Mr. Cunningham clear the first hurdle was Ronald Gentile, MD, a retinal surgeon who operated on him just days after he was forced to leave the cruise ship. Dr. Gentile is no stranger to high-risk cases, but his newest



Ronald Gentile, MD performing emergency surgery on John Cunningham to repair a macula-off retinal detachment.

(Inset) Kira Manuis, MD, using miLOOP to break up a black cataract in the left eye.

patient still posed a considerable challenge. "He had a macula-off retinal detachment in his right eye complicated by a lot of holes and tears in the retina, and by scar tissue that had to be removed gently with micro-forceps," he recalls. The two-hour procedure further involved injection of silicone oil into the vitreous cavity and suturing a scleral buckle to the outside of the eyeball to push the sclera toward the retinal tears.

The removal of the surgical dressing over the right eye days later in Dr. Gentile's office turned into a defining moment for Mr. Cunningham, who works in the dietary department of a nursing home. "I remember Dr. Gentile asking me if I could see, and how astonished he was when I told him I could see the pink stripes in his tie," he recounts. "I can't tell you what a great relief that was for me after thinking the whole time of how easily I could go blind."

The patient's vision soon returned to 20/60, and the path was cleared for the next obstacle: an extremely dense cataract that had robbed Mr. Cunningham of sight in his left eye for the past 10 years. Dr. Gentile brought in another NYEE specialist accustomed to handling surgically complex cases, Kira Manuis, MD, for this part of the extended process. The task she faced—removing a hypermature, black cataract housed in a 33 mm eye that was further compromised by two prior retinal detachments—proved a major challenge even by her standards.

"The lens nucleus in the left eye had become so hardened, sclerotic, and blackened that I couldn't use standard phacoemulsification to break it into small enough pieces for removal without risking posterior capsular and zonular tears, or other surgical



Mr. Cunningham back on the court at LA Fitness Sports Club in North Babylon, NY.

intraocular lens was implanted in the patient's left eye.

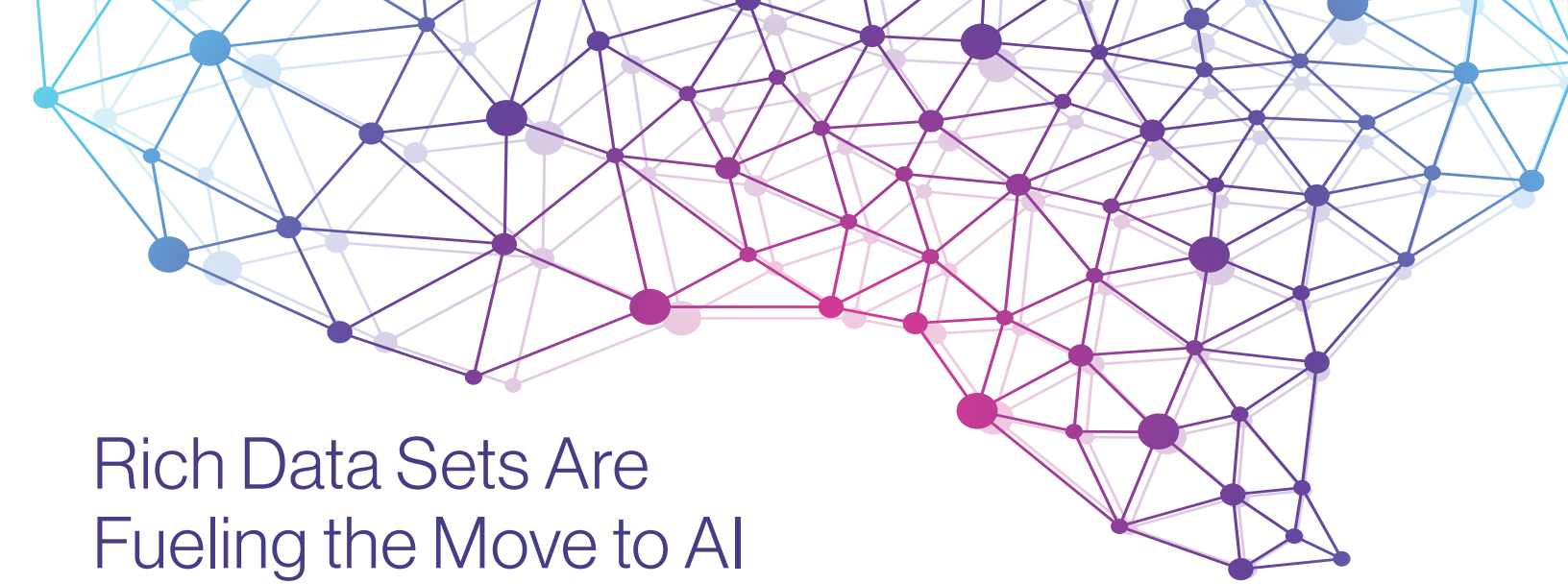Just three months after regaining vision in his right eye, Mr. Cunningham was again able to breathe an audible sigh of relief after surgery to the left. The cataract that had restricted his activities for so many years was now gone. Despite the earlier prognosis by other eye specialists that the left eye had limited potential for vision, it soon improved to 20/30.

Mr. Cunningham's road to recovery included two more surgeries.

Dr. Gentile removed the silicone oil from the right eye, followed by extraction of a secondary cataract by Dr. Manuis. These remaining surgical interventions allowed Mr. Cunningham to fully regain the use of both eyes with stereoscopic vision.

Mr. Cunningham had endured more than most people do in a lifetime, to be sure, but the cumulative effect of four surgeries in 18 months at NYEE allowed him to begin writing a new chapter in his life in which sight turns into a cherished companion rather than a dreaded enemy. He is back on the basketball court, playing the game he has loved since he was five. "The results were quite amazing," he beams, "and for that I can thank a string of awesome doctors."

*Dr. Ianchulev is the inventor and technological founder and developer of a number of ophthalmic technologies, including miLOOP, Intraoperative Aberrometry, CyPass microstent, and Eyenovia micro-therapeutics. He is the holder of multiple patents and receives royalty and milestone payments related to his technologies. He is also the CEO and founder of Eyenovia Therapeutics.*



## Rich Data Sets Are Fueling the Move to AI

Being a technology leader in our field means exploring the extraordinary potential of artificial intelligence (AI) to improve how we diagnose, treat, and manage our ophthalmology patients. To that end, New York Eye and Ear Infirmary of Mount Sinai (NYEE) has embarked on a number of both clinical and research-driven AI projects based on computational algorithms that train on and learn from the rich data sets we have amassed from one of the highest-volume practices in the country.

On the clinical side, plans are underway to deploy AI to autonomously read fundus photographs taken in Mount Sinai primary care offices and alert physicians and their patients, in real time, to potentially serious ocular problems that need immediate follow-up. "Instead of having to chase the patient once they've left the office and returned to their busy lives, we can plug them into any additional care they may need through a preliminary read of their image with the help of AI," explains Sophia Saleem, MD, Director of Telemedicine at NYEE and Assistant Professor of Ophthalmology at the Icahn School of Medicine at Mount Sinai. "This approach will allow us to know at the point of care if a patient with diabetes has macular swelling, for example, and needs to see a retinal specialist. It's as much about retaining people in the health system as it is about better coordinating their care."

The NYEE screening program in primary care offices began several years ago under the direction of Dr. Saleem to identify individuals with diabetic retinopathy, who typically do not pay visits to an eye doctor. The way the program—known as tele-

ophthalmology—currently works is that patients have non-mydratric images of the back of the eye taken by a trained medical technician using a stationary fundus camera. These images are then sent via a secure network to NYEE, where they are read days later by an ophthalmologist. A report is sent to the patient's primary care physician if an abnormality is detected.

Artificial intelligence now promises to significantly streamline that process, cutting the wait time for an initial read from days to minutes. An algorithm that now resides on NYEE's tele-ophthalmology image platform has been trained and validated. Considering the progress made so far, Dr. Saleem is looking forward to the next phase. "At this point, we are looking to integrate AI technology into the primary care office's workflow to reduce the amount of time to schedule follow-up for patients who need it. Shifting our workflows away from traditional asynchronous telemedicine, we hope to demonstrate how AI will add value for patients in a clinical setting. Because these photographs were taken from patients in primary care settings, they are precisely what's needed to validate this clinical use case," says Dr. Saleem. By the end of the year, she adds, the algorithm should be accessible to thousands of patients at a half-dozen or more sites within the Mount Sinai Health System that are part of the tele-ophthalmology program.

On the research side, NYEE is further looking to employ its data sets to develop deep-learning algorithms that can transcend the ability of humans to offer fresh insights into ocular disease and treatments. "We want to use AI to understand structure-visual

function relationships, and it's critical to have patients in a highly curated database who are representative of the population of the whole country," says Louis Pasquale, MD, Deputy Chair for Research for the Department of Ophthalmology at the Icahn School of Medicine at Mount Sinai and Director of the Mount Sinai/NYEE Eye and Vision Research Institute. "And that's exactly what we have at NYEE, as New York City has a very heterogeneous patient population." In the early stages of the AI initiative, Dr. Pasquale has joined forces with bioinformatics experts at Harvard University to develop high-value data sets to which NYEE is a major contributor. NYEE's own in-house expertise with software algorithm development is expected to further fuel efforts to use AI to explore structure-functional research, according to Dr. Pasquale.

In one application that hints at the vast possibilities ahead, Dr. Pasquale's team has used AI to automate the assessment of nailfold capillary imaging and identify a morphologic change known as tortuosity, seen in exfoliation glaucoma. For this project, scientists trained convolutional neural networks, using 4,000 training steps each, to analyze two-minute nailfold capillary videos of the microvasculature of fingernail beds of individuals to distinguish low tortuosity from high tortuosity. Using conventional scoring methods to generate tortuosity scores is otherwise time-consuming and requires a tedious manual review of videos.

"Down the road, we'd like to train the AI algorithm to make other determinations about an individual's future health based on their nailfold capillary imaging," says Dr. Pasquale. "The sky is really the limit when it comes to what these neural networks can do."

## Ushering in a New Era of Unlimited Potential With the First Robot in the U.S. For Precision Ophthalmic Surgery

While robots are no strangers to operating suites for cardiac, orthopedic, and many other types of surgery, no device has achieved the three-dimensional precision needed to operate inside the human eye. That's about to change as New York Eye and Ear Infirmary of Mount Sinai (NYEE) gears up to introduce the first robotic interventional system for ocular surgery to the United States. NYEE is working closely with the Dutch developer of the system, Preceyes, to secure approval from the Food and Drug Administration (FDA) to begin trials in the U.S., creating future applications that could transform the fields of retina, cornea, cataract, and glaucoma surgery.

"The robotic system will increase by tenfold—down to 10 microns—the precision of microsurgical intervention," says Tsoncho Ianchulev, MD, Professor of Ophthalmology at the Icahn School of Medicine at Mount Sinai, who is collaborating with engineers at Preceyes on the system installation. "It also eliminates tremors in the surgeon's hand, paving the way for new interventional possibilities, development of important new instrumentation, and surgical interventions in nearly every specialty and subspecialty in ophthalmology."

In a two-phase trial involving 12 patients at John Radcliffe Hospital at the University of Oxford in England (*Nature Biomedical Engineering*, June 2018), the robot performed a dissection of an ultrathin epiretinal membrane and the inner limiting membrane covering the macula, as well as the injection of a therapeutic drug (recombinant tissue plasminogen activator) under the retina through a fine needle, to dissolve sight-threatening hemorrhages. All surgeries were completed successfully with patients experiencing improvement in their vision.

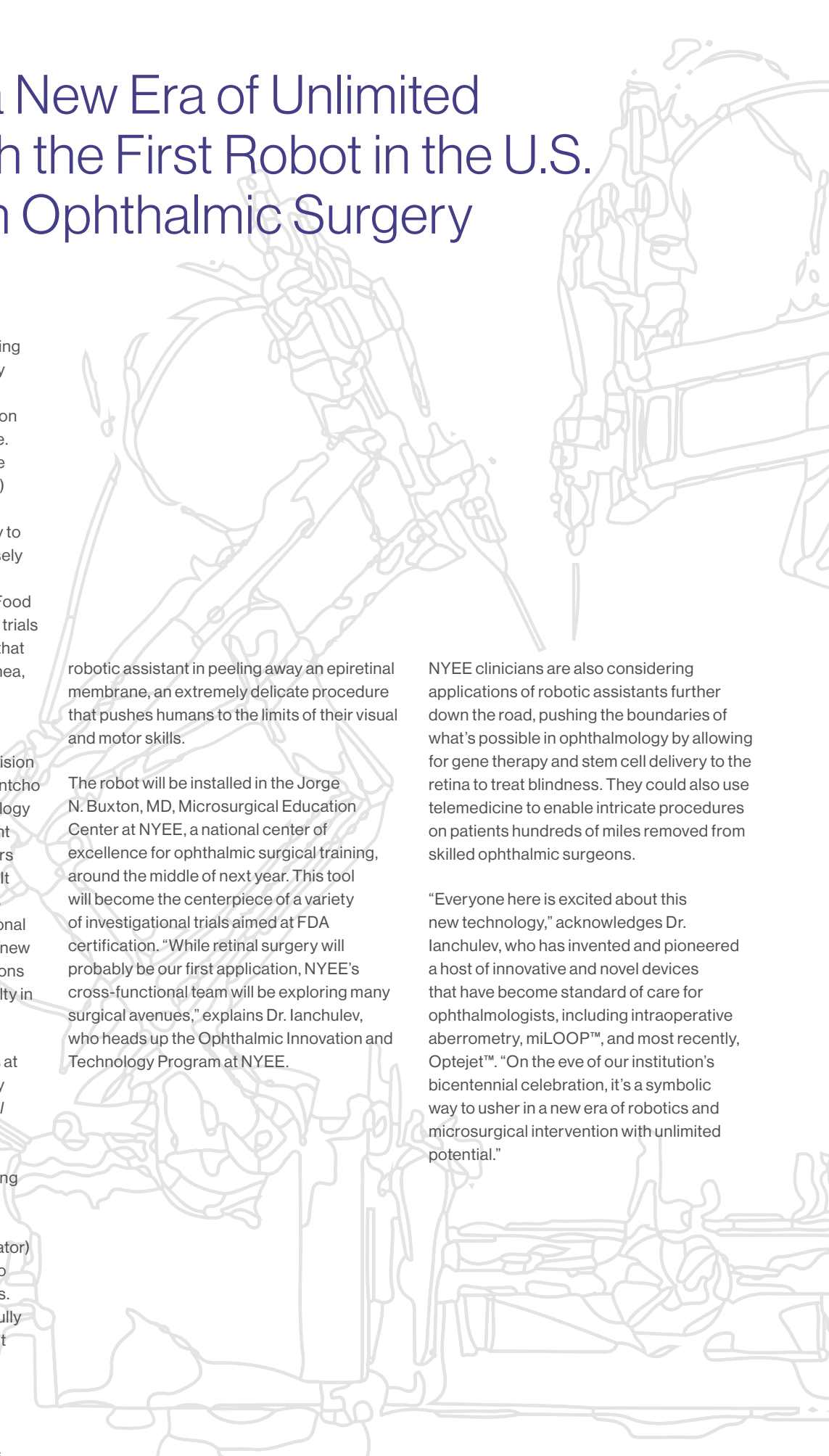A new study at Rotterdam Eye Hospital in the Netherlands is further testing the precision and accuracy of the Preceyes

robotic assistant in peeling away an epiretinal membrane, an extremely delicate procedure that pushes humans to the limits of their visual and motor skills.

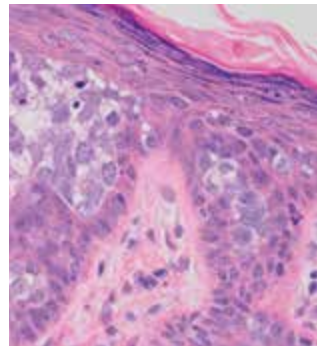
The robot will be installed in the Jorge N. Buxton, MD, Microsurgical Education Center at NYEE, a national center of excellence for ophthalmic surgical training, around the middle of next year. This tool will become the centerpiece of a variety of investigational trials aimed at FDA certification. "While retinal surgery will probably be our first application, NYEE's cross-functional team will be exploring many surgical avenues," explains Dr. Ianchulev, who heads up the Ophthalmic Innovation and Technology Program at NYEE.

NYEE clinicians are also considering applications of robotic assistants further down the road, pushing the boundaries of what's possible in ophthalmology by allowing for gene therapy and stem cell delivery to the retina to treat blindness. They could also use telemedicine to enable intricate procedures on patients hundreds of miles removed from skilled ophthalmic surgeons.

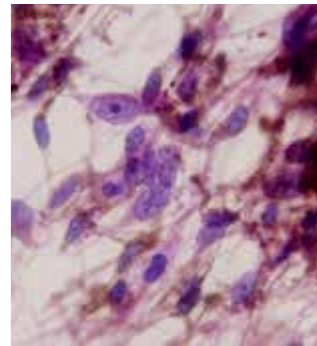
"Everyone here is excited about this new technology," acknowledges Dr. Ianchulev, who has invented and pioneered a host of innovative and novel devices that have become standard of care for ophthalmologists, including intraoperative aberrometry, miLOOP™, and most recently, Optejet™. "On the eve of our institution's bicentennial celebration, it's a symbolic way to usher in a new era of robotics and microsurgical intervention with unlimited potential."



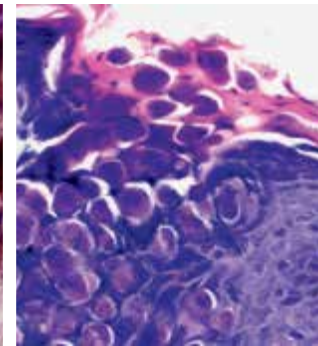
# Ophthalmic Pathology Referral Service Is Filling a Need On a National Scale



Sebaceous carcinoma showing pagetoid invasion in epidermis



Uveal malignant melanoma on FNA



Molluscum contagiosum, eyelid histology

To meet the critical need for ophthalmic pathology services within our own hospital, as well as other institutions, New York Eye and Ear Infirmary of Mount Sinai (NYEE) is responding with a fully equipped and staffed Ophthalmic Pathology Referral Service, part of the Pathology and Laboratory Medicine Department. A team of three ocular pathologists skilled in diseases of the eye and neighboring tissues is examining and processing biopsies and providing ophthalmologists at hospitals, surgical centers, and ophthalmology practices with vital information about the cause, pathogenesis, and prognosis of specific disorders.

"We're prepared to deliver these results quickly and accurately to physicians to help them determine the most appropriate course of treatment for their patients," says Jodi Sassoon, MD, Director of the Pathology and Laboratory Medicine Department at NYEE. "Between the laboratories of NYEE and Mount Sinai, we have access to a breadth of resources few other facilities can match, including flow cytometry for lymphoma studies, immunohistochemistry, special stains, and direct immunofluorescence. Thanks to these capabilities, we can handle everything from simple biopsies to very intricate ophthalmic pathology."

Given the existence of no more than a handful of comprehensive ophthalmic

pathology labs in the country, NYEE is set to expand its services on a national scale. Dr. Sassoon, who previously built a private eye pathology practice that processed over 12,000 specimens a year, is now relying on a team of veteran hospital-based pathologists to exponentially grow the referral business. "We're providing both consultancy and primary diagnosis to our clinical customers as we look to develop the most comprehensive menu of pathology services anywhere," asserts Dr. Sassoon. Results are already being seen, as increasing numbers of small hospitals along with ambulatory surgical centers, and private practices are sending their eye specimens to NYEE for evaluation.

"We are diagnosticians first and foremost," says Dr. Sassoon, who brings more than 32 years of experience in the field of clinical, anatomic, and ophthalmic pathology to her position. "We work closely with clinicians to figure out what is wrong with their patients, and this typically requires us to draw on our skills and training in microbiology, histopathology, and polymerase chain reaction." The "orbital glial heterotopia" case described in this Specialty Report on page 18 underscores the value of close collaboration and the importance of ophthalmic pathology in treating complex cases.

Customer service will be an important feature of the service, with 24- to 48-hour turnaround on most specimens, though special stains

for infection or comparable tests may require an extra day. And easy-to-read pathology reports, turnkey specimen collection, and direct access to Dr. Sassoon and her team—which includes pathologists Codrin Iacob, MD, FCAP, and Nada Farhat, MD—are other ways in which NYEE's Pathology and Laboratory Medicine Department is responding to the needs of clinicians. The recent addition of immunohistochemical stains to the laboratory repertoire has helped enhance processing times, so that they meet or exceed industry standards. Formalin fixation to preserve histology specimens of the conjunctiva, cornea, eyelid and surrounding skin, iris, optic nerve, orbital tissue, pterygium, and trabecular meshwork is also part of our guideline-driven process for gross examination and slide preparation.

As NYEE begins its third century of operation, ophthalmic pathology will clearly play a key role in its forward-looking clinical and research agenda. Beyond the enhanced diagnoses, national recognition, and added revenues, such a specialized service promises to bring, it will help to complement our residents and fellows education programs. "We're part of a large academic center," points out Dr. Sassoon, "which means our pathologists are ready to contribute their considerable knowledge about tumors, inflammation, infection, and much more to train the next generation of talented ophthalmologists."

## Pathology Referral Service at NYEE

310 East 14th Street  
Room 317  
New York, NY 10003

**Jodi Sassoon, MD**  
**212-979-4156**  
JSassoon@nyee.edu

# New Retinal Capillary Density Mapping Technique Could Provide an Advanced Window on Disease

In an unfolding age of preventive medicine, nothing is more critical to clinicians than being able to detect disease at its earliest stage and then track its progression. Optical coherence tomography angiography (OCTA) is bringing that diagnostic approach to life in the ophthalmology imaging lab, and New York Eye and Ear Infirmary of Mount Sinai (NYEE) researchers have taken a significant next step by developing a simple and intuitive way to assess the status of parafoveal capillary density that might suggest future pathology. The technique, reported in *Translational Vision Science and Technology* (May 2019), describes a novel capillary deviation mapping technique that performs qualitative and quantitative assessment of capillary density in an individual patient's central macula, and compares it to the normative distribution of control subjects.

"Instead of just looking at a map of capillary density, this technique enables clinicians to pinpoint just the significant regions of subnormal capillary density, taking into account the normal variability of a population of control subjects," explains Richard Rosen, MD, Deputy Chair of Clinical Affairs and Director of Ophthalmic Research at NYEE, and co-author of the study. "This is particularly useful in the early stages of a disease like diabetic retinopathy when it's not clear whether gaps between capillaries are acceptable variants, or outside the expected range of normalcy." Just as significantly, Dr. Rosen adds, "This is the next step in making quantitative analysis of vascular disease useful for clinicians at every level of expertise."

NYEE has become a global leader in the development of state-of-the-art analysis with the recently introduced technology of OCTA imaging, creating software tools to help predict onset of ocular disease. Dr. Rosen and Yuen Ping Toco Chui, PhD, Director of the David E. Marrus Adaptive Optics Imaging Laboratory and Associate Professor of Ophthalmology at the Icahn School of Medicine at Mount Sinai, have leveraged their experience in adaptive optics vascular analysis software to turn

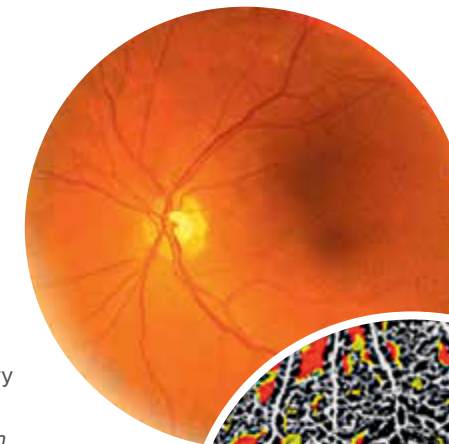


Fig. 1

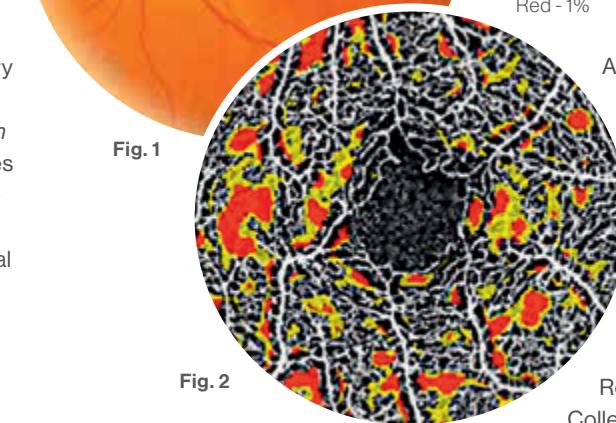


Fig. 2

**Fig. 1:** Fundus image of diabetic retina not showing any visible sign of retinal disease.

**Fig. 2:** OCT angiography perfusion deviation mapping of same eye reveals early significant capillary loss.

**Deviation Map, % of Distribution**  
Yellow - 5%  
Red - 1%

OCTA imaging into a practical tool for judging progression of vascular disease. "By creating color-indexed maps which highlight subnormal areas of capillary density, we've tried to make it easier for clinicians who are typically busy seeing patients and don't have a lot of time to interpret the raw image data," explains Dr. Chui. "Our mapping technique gives them an intuitive assessment of retinal regions with abnormal capillary density."

Central to the parafoveal capillary density deviation mapping approach is a normative database, developed in collaboration with Joseph Carroll, PhD, and colleagues at the Medical College of Wisconsin, that provides clinicians with a benchmark to differentiate normal, age-related changes from early subclinical disease. "It's always been challenging, early in the course of a disease, to predict how rapidly the pathology is progressing and how aggressive you need to be, to address it appropriately," observes Dr. Rosen, who is also System Chief of Retina Service at Mount Sinai Health System and Professor of Ophthalmology at the Icahn School of Medicine.


As a critical part of its study, the NYEE-led team also examined the influence of age and image signal strength index (SSI) on parafoveal capillary density values—vital factors in the accurate interpretation of OCTA data. Indeed, prior OCTA studies had suggested a decrease in parafoveal vessel density with age in otherwise healthy individuals.

Researchers at NYEE and Medical College of Wisconsin found, however, that the effects of age on parafoveal density may have been skewed in past studies by failure to control for SSI variability. "Reduced clarity of the ocular media in older patients due to cataracts, corneal disease, or other age-related ocular degradations can result in lower SSI, leading to reduced measures of parafoveal capillary density," notes Dr. Chui. "This is a confounding factor that can cause misinterpretations of the real vascular density in older patients." The new deviation mapping approach accounts for both aging and the impact of SSI in determining retinal regions with abnormal density.

The next step for our imaging group is to create a stand-alone version of this software, which will enable us to share our analysis with other groups interested in identifying subnormal capillary density in their own patients. "Our overarching goal," emphasizes Dr. Rosen, "is to translate the many quantitative methods we've developed into practical clinical tools that will help clinicians to make important everyday decisions, critical to the quality of care of their patients."



# Taking Retinal Imaging To the Cellular Level



Breakthroughs in treating elusive diseases like macular degeneration and glaucoma will be facilitated by modalities for imaging their unique vascular and blood flow characteristics. Scientists are now closer than ever to achieving this, thanks to impressive advances in optical coherence tomography angiography (OCTA), and no institution is working harder to bring that science into the mainstream than New York Eye and Ear Infirmary of Mount Sinai (NYEE).

In the field of ocular imaging, speed is paramount in order to capture the movement of blood cells across the intricate network of veins and arteries of the eye. Researchers at the David E. Marrus Adaptive Optics Imaging Laboratory at NYEE have developed a super-fast, 1.64 MHz OCTA system that is now able to take retinal imaging to the cellular level. "Within the retina are at least 10 layers of cells that house many of the changes that trigger disease," explains Richard Rosen, MD,

Deputy Chair for Clinical Affairs and Director of Ophthalmic Research at NYEE. "Having this high-speed OCTA capability will allow us to study many individual cell types that we couldn't visualize before, and that will put us in the forefront of imaging research into glaucoma, macular degeneration, and other intra-retinal diseases."

Leading the development of this technology is Justin Migacz, PhD, a biomedical engineer and postdoctoral imaging fellow in Dr. Rosen's lab, who began the project during his PhD work at the University of California-Davis Medical Center in Sacramento. In an article in *Biomedical Optics Express* (December 2018), Dr. Migacz describes how OCTA, with its rapid frame rate, enables visualization of high-speed blood flow within the choroid and choriocapillaris, at a level never seen before. The choroidal vessels form a complex vascular network, and it is believed that defects of the

Justin Migacz, PhD, in the David E. Marrus Adaptive Optics Imaging Laboratory at NYEE

**Fig. 1 and 2.** A comparison of choriocapillaris (Fig. 1) and retinal (Fig. 2) images from the same subject on two different OCTA systems. Images from the commercially-available system (1A and 1B) pale in comparison to those taken with the research-grade, ultrahigh-speed OCTA system images shown on the right (2A and 2B).

choroid—particularly the choriocapillaris layer—may play a significant role in the early stages of age-related macular degeneration.

"With OCTA we can distinguish much more clearly than before the motion of the choriocapillaris from other distracting features in the image," says Dr. Migacz. "It essentially allows you to see the outline of the blood vessels in fine detail and with a high level of confidence." In turn, this high-resolution visualization provides a window on how blood

vessels are structurally changing—becoming more brittle, or thinning out—and how this decay affects progression of the disease. Because OCTA exposes each individual branch of the blood vessels in minute detail, Dr. Migacz is hopeful this magnification will also reveal how and when the disease starts, enabling treatment to begin at the earliest possible stage.

In addition to OCTA, adaptive optics scanning laser ophthalmology (AOSLO) provides NYEE clinicians unprecedented cellular-level views of retinal microvascular structure and blood flow. Researchers in the Marrus Adaptive Optics Imaging Laboratory are now working on marrying the high-resolution strength of AOSLO with the high-speed advantages of OCTA to reveal a piece of the glaucoma puzzle that has evaded researchers for years: the role of ganglion cells, the neurons that relay information from the retina to the brain. "This would take us to another level in terms of looking at the actual histological structures within the retina," points out Yuen Ping Toco Chui, PhD, Director of the Marrus Adaptive Optics Imaging Laboratory and Associate Professor of Ophthalmology at the Icahn School of Medicine at Mount Sinai. Collaborating with NYEE on this imaging project are researchers from Stanford and UC-Davis's Department of Ophthalmology.

Undergirding the cutting-edge work of Drs. Migacz and Rosen in the adaptive optics lab is the goal of transferring their findings to the clinic so they can benefit patients. This will first require working with and convincing device manufacturers and system developers of the enormous potential that vasculature imaging—exemplified by what NYEE has achieved in the lab—holds both commercially and clinically. "We want to make this technology user-friendly so it can be readily adopted in the clinic," emphasizes Dr. Migacz. "My personal hope is that our work will open the door to developing treatments for patients sooner, and monitoring them to ensure they are effective."

## After-Hours OCT Could Be a Sight Saver For Some Patients

Optical coherence tomography (OCT) has proven to be a powerful diagnostic tool for people with eye emergencies—but only if their visit to an outpatient setting happens to occur during normal hours when skilled imaging personnel are on duty. What if this technology was available in eye clinics and hospital emergency rooms after-hours and on weekends, when many cases of visual loss and ocular trauma actually occur?

New York Eye and Ear Infirmary of Mount Sinai (NYEE) has made a determined effort to find out. In the first study of its type, researchers expanded access to automated OCT in a resident- and fellow-staffed, eye walk-in clinic setting after normal hours to weigh its impact on improving the accuracy and timeliness of diagnosing emergent eye disorders, and optimizing patient outcomes.

They had a strong historical precedent. Two other imaging modalities—ocular ultrasound and non-mydriatic fundus photography—were already being deployed in emergency settings for use by non-ophthalmology practitioners to pinpoint ocular pathologies that might otherwise be missed, or misdiagnosed. Could OCT improve on their success in triaging patients and channeling them to the appropriate care specialists and clinics?

As reported in *BMJ Open Ophthalmology* (January 2019), the NYEE study found that greater access to OCT in after-hours settings facilitated optimal care management, improved patient satisfaction, and reduced practitioner stress levels, according to the 25 residents and fellows who were surveyed. "Having availability of this superior diagnostic capability during off-hours and on weekends can potentially save the vision of a lot of our patients," notes Richard Rosen, MD, Deputy Chair for Clinical Affairs and Director of Ophthalmic Research at NYEE, and coauthor of the study. "Being able to make the distinction between an acute episode of wet macular degeneration, which developed overnight, and something more benign like central serous retinopathy, allows us to triage patients in a much more effective manner."

Indeed, the study demonstrated several advantages of having OCT at the point of care, available for diagnosis and management of acute complaints and ocular emergencies. One case in point is central retinal artery occlusion (CRAO),

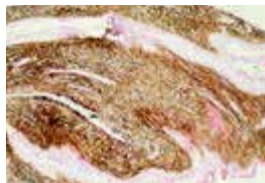
for which a fundus examination alone may fail to reveal a cherry red spot or retinal opacification in up to 42 percent of cases. Optical coherence tomography, on the other hand, provides much higher sensitivity for detecting ischemia in acute CRAO. The case of a 64-year-old woman who arrived at the walk-in eye clinic complaining of distorted vision brought the point home. Upon funduscopic examination, she was found to have a small hemorrhage in the nasal macula. OCT imaging of that area picked up a subretinal hemorrhage and exudate, consistent with a choroidal neovascular membrane. This prompted ophthalmologists on duty to refer the patient to the Retinal Clinic where a fluorescein angiogram confirmed choroidal neovascularization, for which prompt anti-vascular endothelial growth factor therapy was initiated.

The 18 residents and 7 fellows who participated in the study were trained in less than half an hour to operate the OCT (Optovue, Inc.) system, capable of scanning the macula (en face, 3D slices, and thickness map), optic nerve, and anterior segment (angle, corneal pachymetry). The device employs computerized voice directives in multiple languages to help patients align themselves for optimal positioning. All of the participating physicians found OCT to be helpful, with the preponderance opining that it changed clinical management and improved patient satisfaction. Richard Kaplan, MD, a retina fellow at NYEE and coauthor of the study, explains further: "After-hours access to OCT allowed ophthalmologists to promptly show patients the images, and explain to them the recommended course of therapy and prognosis. Oftentimes, patients left the clinic with their fears or concerns assuaged by the state-of-the-art imaging."

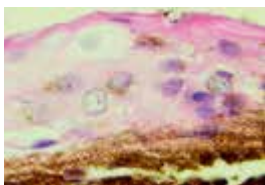
While the study focused on eye-only clinics, it underscored the importance of extending OCT to general emergency departments, where it could augment fundus photography. "We're hoping this concept could become a mainstay tool in hospital settings, as well as in urgent care eye clinics," points out Dr. Rosen. "It's important for emergency room physicians to know that automated OCT can help them make sound judgments in cases that may be outside their area of expertise."

# NYEE Team Saves Eyesight in Toddler With Aggressive Cystic Epithelial Downgrowth

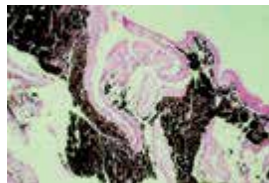
When Edward Gil's mother, Mary Linn Gil, noticed that the 18-month-old's right eye was red, she thought it might be an irritation caused by shampoo so, initially, she wasn't overly concerned. But when it didn't dissipate the next morning and Edward kept rubbing his eye, she administered over-the-counter eye drops and made an appointment with his pediatrician. By the following day, she noticed a "bubble" in that eye. The pediatrician referred them to a local hospital, where the examining doctor diagnosed astigmatism and prescribed eyeglasses. Ms. Gil didn't have confidence in that assessment and asked for another referral. The doctor referred her to New York Eye and Ear Infirmary of Mount Sinai (NYEE), and she immediately took him to the Hospital's eye walk-in clinic.



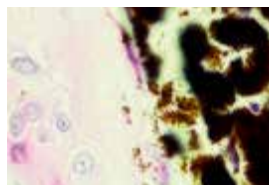
**Anterior 1:** Stratified epithelium is seen covering iris stroma containing powdery melanin pigment granules, features diagnostic for epithelial downgrowth along the anterior surface of the iris.



**Anterior 2:** Epithelium shows benign cytologic features including low nuclear cytoplasmic ratio and smoothly contoured nuclei. Powdery melanin granules of iris stromal origin are seen in cytoplasm of epithelial cells.



**Posterior 1:** The same epithelial downgrowth is found overlaying the pigmented epithelium along the posterior surface of the iris characterized by larger diameter melanin granules.



**Posterior 2:** Cytologically bland epithelial cells are seen harboring intracytoplasmic melanin pigment granules of iritic pigmented epithelial origin.

NYEE resident Annie Nguyen, MD, who first examined Edward, diagnosed a full thickness corneoscleral laceration, and the "bubble" described by Ms. Gil was actually an iris prolapse. This was a shock to Ms. Gil, as she had not witnessed or recalled trauma. Dr. Nguyen scheduled Edward for surgery the following day, fearing a delay might result in vision loss. She repaired the laceration with six stitches. Edward's postoperative regimen included antibiotic eye drops and ointment, which were difficult to administer due to his age and also because he is autistic, but his mother persevered.

In the months that followed, doctors performed several exams, some in the office and others under anesthesia, including suture removal. Edward's autism made these examinations challenging, regularly requiring extra time, multiple attempts, and several providers to complete. Six months after surgery, doctors found signs of deteriorating vision even though his mother had done a good job patching to

reverse amblyopia. Under anesthesia, they discovered a cystic lesion behind the iris within the posterior chamber of the eye in the area of the corneoscleral scar. From its clinical appearance and history, the team suspected cystic epithelial downgrowth. Given the risk that another surgery might cause a cataract or more aggressive recurrence, they monitored him closely, but over the next six weeks, Ms. Gil noticed that Edward's vision seemed to worsen, and that he was no longer attentive or playful when patched for amblyopia treatment.

At the next examination under anesthesia, less than two months after its discovery, the lesion had now almost doubled in size. Measuring 8.06mm long by 4.45mm wide, the cyst covered more than 50 percent of the pupil, and was visible through an undilated pupil, obscuring the visual axis. It had pushed the overlying iris against the corneal endothelium and, after dilation, was found to be tilting the lens posteriorly. The time for observation was over.

"Complete surgical excision was the best option to give us the greatest chance of maintaining Edward's vision with the least number of complications," said Douglas Fredrick, MD, Deputy Chair for Education, Department of Ophthalmology at the Icahn School of Medicine at Mount Sinai, and Chief of Pediatric Ophthalmology, Mount Sinai Health System. "Sensory pathways are especially important in children with autism and Edward needed to clear the visual axis so that the visual processing region of his brain could continue to develop."

The surgical team, which included Phillip Tenzel, MD, NYEE's first pediatric ophthalmology and strabismus fellow, used an endoscope to visualize the cyst and its attachment to the iris root, enabling them to successfully remove the cyst in the safest, most controlled manner. After the iris and lens capsule were carefully teased away, surgeons dissected the scar tissue and aspirated the cyst, amputating it from its dense peripheral adhesions.

Four months later, Edward's pupil was round and his astigmatism was improving, with no signs of cyst recurrence or a cataract. Dr. Fredrick attributes their success to NYEE's comprehensive team of specialists geared toward pediatric patients and their families, which also included Erin Walsh, MD, and Steven Rosenberg, MD, Co-Directors of Pediatric Ophthalmology and Strabismus at NYEE, who lent their expertise to Edward's pre- and postoperative care. "The Department of Pediatric Ophthalmology at NYEE is known for treating children with some of the most complex and rare eye problems," he says. "We combine extensive surgical expertise with highly trained technicians and OR staff skilled at using state-of-the-art equipment. This, coupled with postoperative vision assessment and amblyopia treatment, facilitated by a team of orthoptists with more than 90 years of combined clinical experience working with very young and non-verbal patients, allows us to provide the best chance for excellent visual outcomes."

In Dr. Fredrick's estimation, Edward's case highlights how well this continuum of care benefits patients and their families. And Dr. Tenzel's fellowship training really prepared him to deal with Edward's unique needs. In addition to providing scrupulous care, Dr. Tenzel became part of Edward's support system, skillfully dealing with the boy's family, speaking to Edward's mother daily, and coaching her on how to give him the special care required to ensure his recovery. "It is this combination of skills and experience that has allowed NYEE to become a center of excellence for pediatric ocular conditions and visual disorders," says Dr. Fredrick, "and will continue to make us a place where doctors want to train to become the best in their field."

Edward's mother is thankful for the NYEE staff. "I never would have imagined that he would get the kind of attention and care he received," said Ms. Gil. "The staff were all so patient and accommodating, and they understood him in a way no one else could."

## A New Supplement 'Cocktail' Shows Promise in the Fight Against Glaucoma

Fascinated by an article that came across his desk in 1996 on ginkgo biloba extract (GBE), Robert Ritch, MD, Director of Glaucoma Research and Surgeon Director Emeritus at New York Eye and Ear Infirmary of Mount Sinai (NYEE), had an epiphany. If an over-the-counter supplement that combined the antioxidant, neuroprotective, and mitochondrial protective properties of GBE with other similar compounds were developed, could it prevent oxidative damage and reverse the mitochondrial dysfunction that has been increasingly implicated as a cause of retinal ganglion cell death in patients with glaucoma? A 1999 study from NYEE, published in the *Journal of Ocular Pharmacology and Therapeutics*, had already shown that GBE improved blood flow to the central retinal artery by 24 percent.

Twenty-three years later, that brainstorm has led to a new product on the market known as GlaucoCetin®. Developed by Dr. Ritch, the initial proprietary formula, GlaucoHealth™, was a combination of eight ingredients, including GBE, curcumin (a broad-spectrum anti-inflammatory agent), alpha-lipoic acid, citicoline, coenzyme-Q10, N-acetyl-cysteine, grapeseed extract, and green tea extract—a cocktail for enhanced eye health, which showed particular promise against glaucoma, the leading cause of vision loss in this country.

In a study of 14 patients, Dr. Ritch and collaborators from NYEE and Columbia University found that GlaucoHealth reversed mitochondrial flavoprotein fluorescence, an indicator of mitochondrial oxidative stress, as measured by retinal metabolic analysis. The study was performed under an investigational new drug application from the U.S. Food and Drug Administration. When considering the results of the study, Dr. Ritch believes that it "will serve as a strong proof of concept for future trials testing glaucoma supplements."

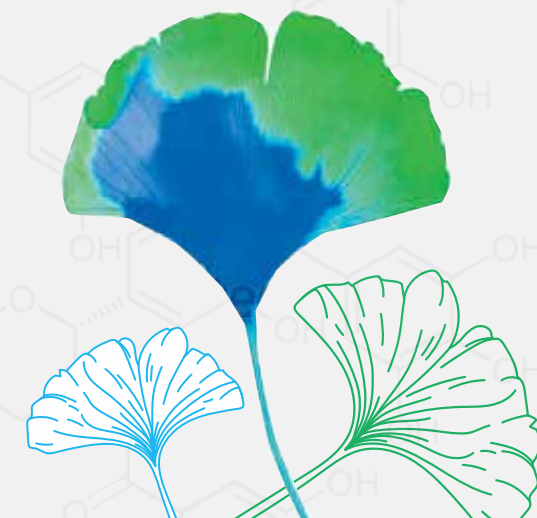
GlaucoHealth is now marketed as GlaucoCetin, a second-generation product introduced to the public in July 2019, with an

enhanced combination of ingredients, including niacinamide, L-taurine, and a proprietary flavonoid complex. "Through its proven ability to stabilize mitochondria, GlaucoCetin will hopefully slow down the progression of glaucoma and preserve vision in patients for much longer periods of time," says Dr. Ritch, internationally acclaimed for his glaucoma research over the years. "And that could shift treatment to an earlier, more manageable stage of the disease, before the retinal ganglion cells begin to die."

GlaucoCetin is manufactured and distributed by Guardion Health Sciences, an ocular health sciences and technologies company. It comes in the form of a powder for maximum absorption that is mixed with orange juice or other liquids.

Dr. Ritch views GlaucoCetin as the prototype for other formulations that investigators will be able to draw on and improve with future research. "For now, we've developed the first vision-specific supplement to support and protect the mitochondrial function of optic nerve cells in people with glaucoma," he says. "We're convinced it has tremendous potential not just for market growth, but for giving millions of people an important and promising new way to fight the devastating effects of this disease."

*Dr. Robert Ritch is the inventor of a supplement trademarked as GlaucoCetin. Dr. Ritch has not filed a patent for GlaucoCetin; however, he is entitled to a small amount in royalties from Guardion, a company that now owns and markets GlaucoCetin.*



# Seeing Glaucoma In a New Light

Researchers at New York Eye and Ear Infirmary of Mount Sinai (NYEE) are engaging in new avenues of investigation into the treatment of primary open-angle glaucoma (POAG), as well as its possible causes. Two recent studies, one focused on the impact of statins on POAG and the other on the genetic link between diabetes and glaucoma, are paving the way for further research.

## Study Finds That Statins' Use Is Associated With Reduced Risk of POAG

As statins have become among the most pervasive drugs on the market, science has been intrigued by the idea that they might benefit not just people with high cholesterol, but those with cancer, inflammatory disease, and neurologic disorders. Studies have also suggested that statins may be associated with lower risk of POAG, though the results have been uncertain. Nor has convincing evidence surfaced about the relationship between high cholesterol levels and POAG.

A study led by Louis Pasquale, MD, Deputy Chair for Research for the Department of Ophthalmology at the Icahn School of Medicine at Mount Sinai and Director of the Mount Sinai/NYEE Eye and Vision Research Institute, in collaboration with researchers at Harvard Medical School, has shed some valuable light on these questions through the most extensive statin-use trial to date, a population-based cohort analysis of nearly 137,000 people who were tracked for 15 or more years. The study found that five or more years of statin use was associated with a 21 percent reduced risk of primary open-angle glaucoma, while every 20-mg/dl increase in total serum cholesterol was linked to a 7 percent increase in the risk of POAG.

Just as interesting as these findings, reported in *JAMA Ophthalmology* (online May 2019), may be what they reveal about the potential neuroprotective mechanisms by which statins lower the risk of POAG. "We believe that statins have a very modest effect on intraocular pressure (IOP), but they may have a more dramatic effect on blood flow to the optic nerve," explains Dr. Pasquale.

It is known that statins affect the activities of myosin II adenosine triphosphatase and protein kinase in the trabecular meshwork, serving to increase nitric oxide production and aqueous outflow, and possibly leading to some IOP lowering. Perhaps more importantly, though, greater production of nitric oxide could increase blood flow to the optic nerve. Other neuroprotective effects of statins include anti-excitotoxic, anti-apoptotic and anti-inflammatory properties that may protect retinal ganglion cells. Several genes involved in cholesterol metabolism (ABCA1, CAV1, ARHGEF12, and DGKG) have also been associated with IOP and POAG in large genome-wide studies.

Findings like these are providing the framework and motivation, according to Dr. Pasquale, for researchers at NYEE to further investigate mechanisms that might explain the protective properties of statins. To be sure, plans are already underway to study people both pre- and post-statin use to determine the effects of the drug on blood flow to the retina—a development Dr. Pasquale terms, "very encouraging and possibly a door-opener to finding mechanisms by which statins may reduce the risk of glaucoma."

## Researchers Find No Genetic Link Between Diabetes and Glaucoma

A recent study published online in the *American Journal of Ophthalmology* (May 2019) has raised questions about past research that suggested a relationship between diabetes and primary open-angle glaucoma. This analysis, involving a genome-wide genetic correlation study, found limited evidence of a genetic link between diabetes- and glaucoma-related traits.

The finding is not consistent with a significant body of epidemiologic and clinical research supporting a positive link between the two pathologies. That research, however, may have been skewed by "detection bias," meaning that people with diabetes go to the eye doctor more frequently, and thus are more likely to have their glaucoma picked up, according to Louis Pasquale, MD, Professor of Ophthalmology at the Icahn School of Medicine at Mount Sinai. "I believe we have to be more careful in future epidemiologic studies to rule out detection bias when studying the relationship between diabetes and glaucoma," he contends.

Nonetheless, the report posits several non-genetic explanations for a positive relationship between diabetes and glaucoma. One is that hyperglycemia results in the accumulation of advanced-glycation end products and fibronectin in the trabecular meshwork, leading to increased intraocular pressure (IOP) in patients with type 2 diabetes. The other points to several lab studies reporting that diabetes exacerbates IOP-induced retinal ganglion cell damage.

"What our paper shows is that there is a high shared inheritability between genes for intraocular pressure and genes for primary open-angle glaucoma," reports Dr. Pasquale. "So even if diabetes is not an endophenotype of glaucoma, intraocular pressure is." As for establishing a genetic linkage between glaucoma and common diabetes traits like high triglycerides and body mass index, however, the researchers emphasized that they came up empty, despite a rich reservoir of data from European-derived populations.

# Unraveling the Clinical Mystery of a Rare Tumor

Concern mounted quickly for Juan Alonzo Munoz when he came to New York Eye and Ear Infirmary of Mount Sinai (NYEE) in 2014, complaining of worsening sight in his left eye and severe headaches. An MRI showed that the 45-year-old had a mass behind his eye that was dangerously close to the left optic nerve. Just as frightening to Mr. Munoz was learning that determining if it was benign or malignant would require a biopsy that could be as bad as the disease itself, resulting in permanent loss of sight.

The years since that initial visit have brought Mr. Munoz the answers he dearly sought. But it took a multidisciplinary team of highly skilled surgeons, a pathologist, and imaging specialists from NYEE to unravel his challenging case. The ability of this team to work cohesively would enable its members to go beyond their conventional roles as clinicians to become medical sleuths who would ultimately unravel a disorder so rare that only 29 cases had been recorded in the medical literature over the past 40 years.

"It was a clinical mystery with enormous implications for the patient because of the nature of what the tumor was and its location in the orbit," recalls Harsha S. Reddy, MD, Director of the Oculoplastic, Orbital, and Reconstructive Surgery Service at NYEE and Mount Sinai Beth Israel, who would become an integral part of that effort.

Initially, team members along with the patient opted for a trial of oral steroids and observation rather than a risky biopsy. Follow-up exams and imaging confirmed the soundness of that decision, since the lesion remained stable. That changed suddenly, though, three years later. "Things went dark in my eye for a while, and then my vision became extremely blurry," recalls Mr. Munoz, who lives with his wife in New York City's borough of Queens. "I was afraid I was going to lose sight altogether in that eye." He returned to NYEE, where tests showed his best-corrected visual

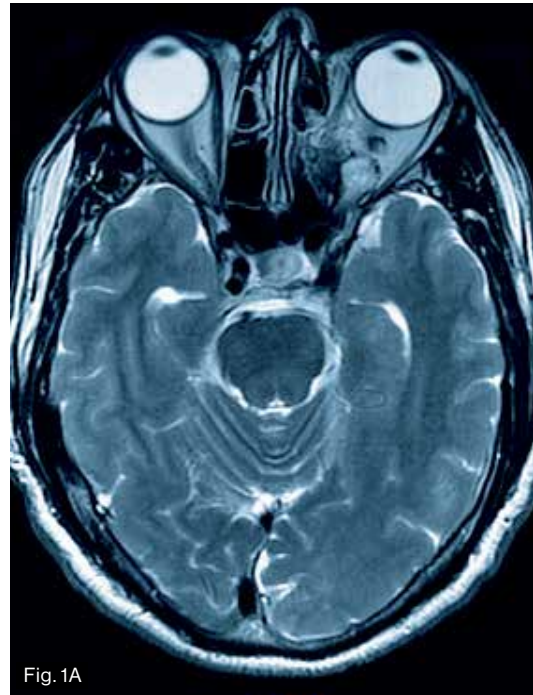

Fig. 1A

**Fig. 1 (A) and (B):** T2 weight Orbital MRI shows hyperintense lesion at the orbital apex.

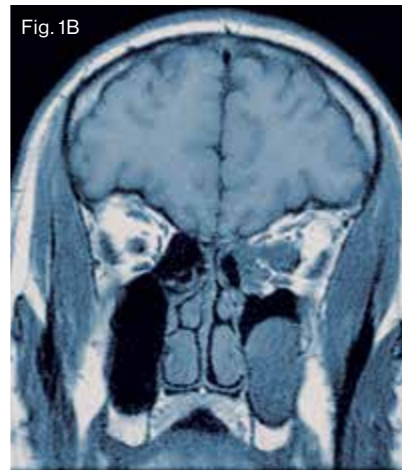


Fig. 1B

acuity had declined to 20/125 in the compromised eye, while his visual field showed worsening superior peripheral vision. Another course of oral steroids was begun, but proved ineffective.

The case had clearly reached a crossroads. "We realized we had to make a call on whether to treat the condition with radiation, which can have serious side effects on the patient's vision, or do a biopsy, which also has potentially severe consequences, but would at least help us make a diagnosis," explains Dr. Reddy, who is an Associate Professor of Ophthalmology at the Icahn School of Medicine at Mount Sinai. After explaining to the patient the magnitude of risk involved, a decision was jointly made: proceed with the biopsy. "I told the doctors I needed some peace of mind," says Mr. Munoz. "I needed to be sure this wasn't a malignant tumor."

The excisional diagnostic biopsy, which removed about 25 percent of the tumor mass, involved a carefully planned and coordinated effort between Dr. Reddy and an ENT surgeon, Patrick M. Colley, MD.

Both were well aware there was no margin for error during the procedure, performed via a left nasal endoscopic approach. "The tumor was deep into the orbit and was sitting right on the optic nerve," explains Dr. Colley, an Assistant Professor of Otolaryngology at the Icahn School of Medicine at Mount Sinai. "The combination of ENT and oculoplastics working together is what made the procedure possible in terms of gaining access to a difficult region. Dr. Reddy was able to point out areas we should be concerned about once inside the orbit, and this allowed both of us to safely obtain the biopsies we needed from the mass."

Other key members of the team were NYEE imaging specialists whose MRI and CT scans helped to characterize the tumor, including its borders and cystic components. Drs. Colley and Reddy relied heavily, too, on a CT navigational imaging system linked to their surgical instruments to provide stereotactic guidance—a valuable set of eyes while exploring the orbital space. Providing crucial forensic input when it came to making the final call was one of NYEE's onsite ophthalmic pathologists, Codrin Iacob, MD, FCAP.



What the histopathologic analysis revealed was a yellow-white mass adjacent to the optic nerve canal, which was found to consist of haphazardly distributed astrocytes in an eosinophilic fibrillary background, with surrounding areas of fibrosis. This led to a long-awaited diagnosis: orbital glial heterotopia, a growth thought to begin as an asymptomatic congenital lesion which, after a period of silent growth, herniates through a defect in the skull to disrupt the visual system either through compression, metabolic disturbance, or other mechanisms.

Fortunately for Mr. Munoz, the tumor was benign, mitigating the need for radiation or other invasive treatment. He and members of his ophthalmic team were elated to learn, in the months that followed, that his tumor growth had been arrested and his vision had improved noticeably and remained stable following the biopsy. Mr. Munoz can also be pleased by another offshoot of his case: NYEE has since formed an Orbital Surgery Service to address other complex orbital cases with the same coordinated care and expertise—all under one roof—that helped

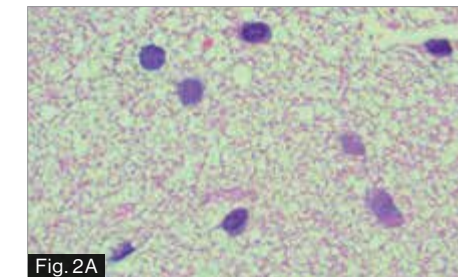


Fig. 2A

From right: Harsha S. Reddy, MD with Juan Alonzo Munoz and Patrick M. Colley, MD

**Fig. 2A:** Astrocytes, showing oval nucleolated nuclei with vesicular chromatin and pink cytoplasmic rimming, are seen spread equidistantly in delicate fibrillary background (neuropil).

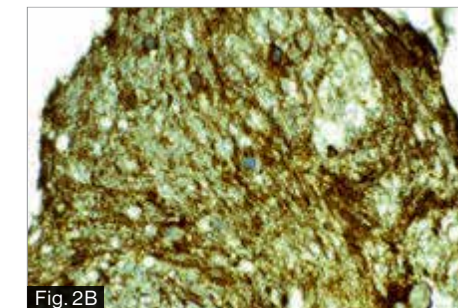


Fig. 2B

**Fig. 2 (B) and (C):** High power and oil immersion views display glial fibrillary acidic protein immunohistochemical staining of the glial fibrillary background. Unstained astrocytic nuclei are easily recognized.

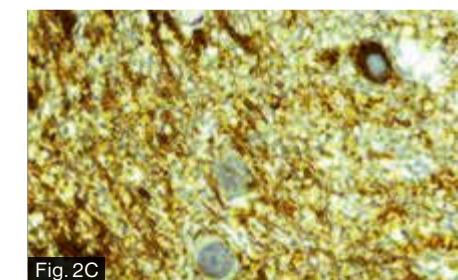
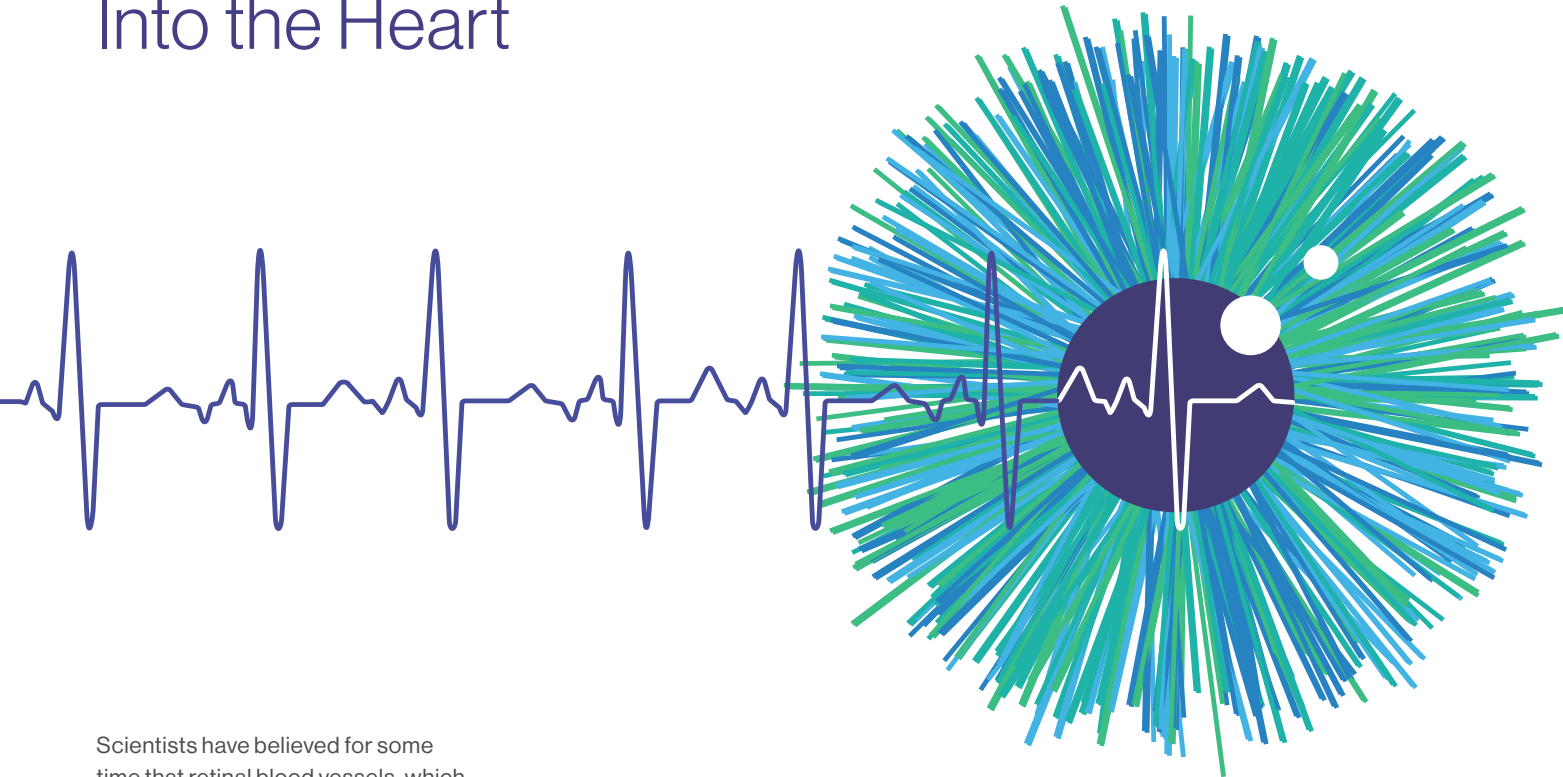


Fig. 2C

resolve his own clinical mystery. "The ability to have access to both ENT and ophthalmic pathology in addition to multiple ophthalmic specialists is invaluable," asserts Dr. Reddy, "and the new Orbital Surgery Service allows us to deliver super-specialized care to patients with complex disorders."

# Retinal Vein Occlusion Now Provides a Window Into the Heart



Scientists have believed for some time that retinal blood vessels, which share the same microvascular anatomy and vulnerabilities as their cerebral counterparts, offer a telltale window into major cardiovascular events like stroke, myocardial infarction (MI), and heart failure. A study by researchers at New York Eye and Ear Infirmary of Mount Sinai (NYEE) of patients with retinal vein occlusion (RVO) has uncovered significant new evidence that this sight-threatening disease has predictive value for subsequent cardiovascular morbidity and mortality.

“Our data show there is a very robust association between retinal vein occlusion and a myriad of very dangerous cardiovascular events,” says Avnish Deobhakta, MD, Assistant Professor of Ophthalmology at the Icahn School of Medicine at Mount Sinai, and coauthor of the meta-analysis involving nearly 475,000 patients. Indeed, the review (*Investigative Ophthalmology & Visual Science*, July 2018) suggests that patients who present with RVO have a 45 percent increased risk of developing a stroke, a 26 percent increased risk of MI, and a 53 percent greater risk of heart failure. Retinal vein occlusion also raises the patient’s

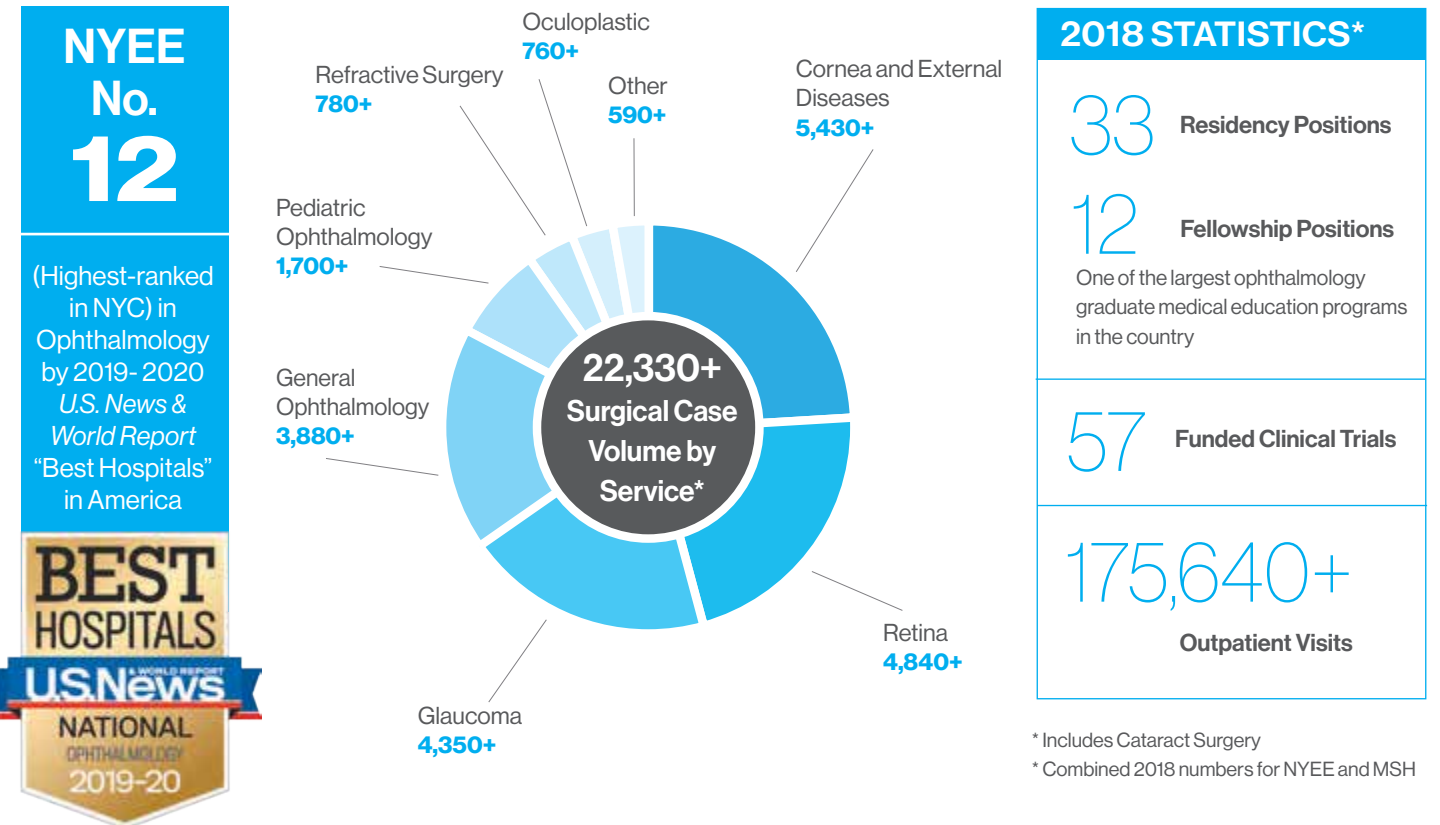
likelihood of developing peripheral artery disease and all-cause mortality, though the study did not find an association with increased risk of cardiovascular death.

Retinal vein occlusion is a major cause of visual impairment in the middle-aged and elderly, affecting about 16 million people globally. Systemic risk factors for RVO include age, as well as atherosclerotic risk factors, such as arterial hypertension, diabetes mellitus, hyperlipidemia, and carotid artery plaque. “If a patient comes in with a retinal vein occlusion, we pretty much assume they have high blood pressure,” notes Christopher Wu, MD, a senior NYEE resident who coauthored the study. The linkage derives from the fact that retinal and cerebral blood vessels have similar anatomical, physiological, and embryological characteristics. Thinning and hardening of blood vessel walls are part of an atherosclerotic process that occurs in not just RVO, but MI and stroke. “Cardiovascular diseases can also affect the small blood vessels of the eye, since they both emanate from the same vascular system,” explains Dr. Wu. “And in many instances the eye is the first sign of trouble.”

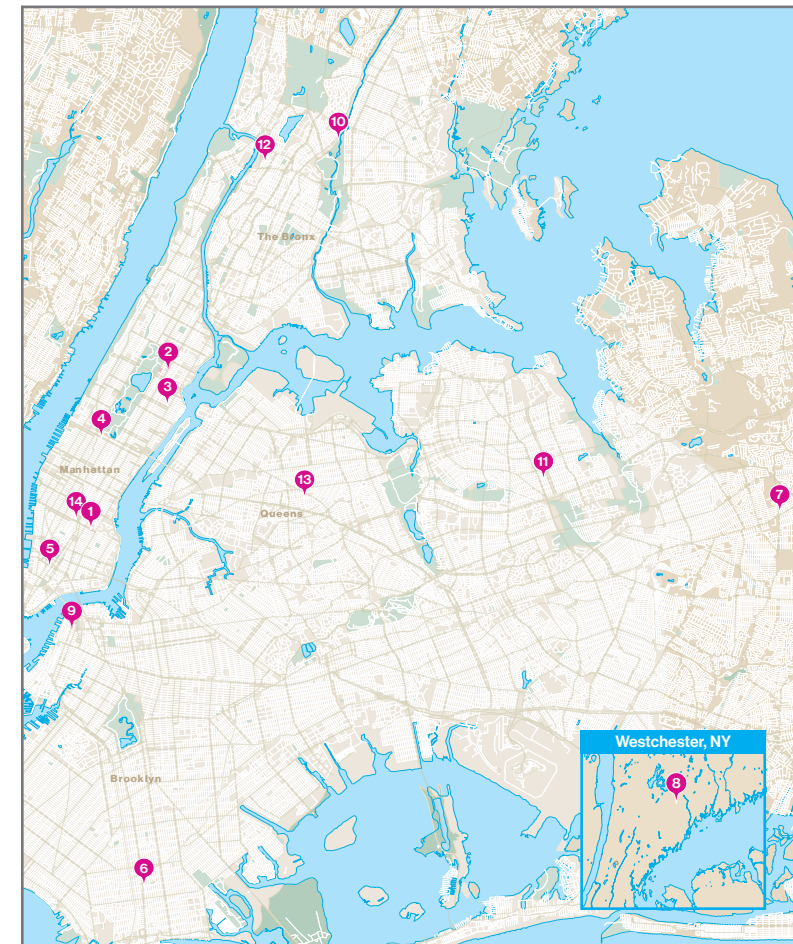
Recognizing its early warning significance, ophthalmologists at NYEE routinely refer RVO patients to primary care physicians and cardiologists for comprehensive workups. However, it’s unclear how widespread that practice is across the rest of the ophthalmology field. In fact, the NYEE study of RVO suggested that it is associated with undertreated cardiac and cerebrovascular disease, thus increasing the chance of myocardial infarction, stroke, and heart failure.

“Our data is compelling enough to suggest that we may need to change our practice pattern to be more vigilant and thorough about referring RVO patients to primary care physicians,” observes Dr. Deobhakta, adding that a more robust handoff to primary care doctors should include recommendations of other specialists patients should see, such as cardiologists, neurologists, or others who treat vascular disorders. “By helping retinal vein occlusion patients identify and control underlying medical conditions like hypertension and diabetes, we as ophthalmologists may be able to play a valuable role in preventing life-threatening cardiovascular events later on.”

## Department of Ophthalmology at a Glance: New York Eye and Ear Infirmary of Mount Sinai (NYEE) and The Mount Sinai Hospital (MSH) / Icahn School of Medicine at Mount Sinai



- Main Campus**
- New York Eye and Ear Infirmary of Mount Sinai**  
310 East 14th Street  
New York, NY 10003
- Satellite Locations**
- NYEE-East 102nd Street**  
17 East 102nd Street  
New York, NY 10029
  - NYEE-East 85th Street**  
234 East 85th Street  
New York, NY 10028
  - NYEE-Columbus Circle**  
200 West 57th Street  
New York, NY 10019
  - NYEE-Tribeca**  
77 Worth Street  
New York, NY 10013
  - NYEE-Midwood**  
1630 East 15th Street  
Brooklyn, NY 11229
  - NYEE-Mineola**  
200 Old Country Road  
Mineola, NY 11501
  - NYEE-Westchester**  
90 South Ridge Street  
Rye Brook, NY 10573



- Affiliated Faculty Practice Sites**
- NYEE-Brooklyn Heights**  
300 Cadman Plaza West  
Brooklyn, NY 11201
- Affiliated Ambulatory Surgery Centers**
- Empire State Ambulatory Surgery Center**  
3170 Webster Avenue  
Bronx, NY 10467
  - North Queens Surgical Center**  
45-64 Francis Lewis Boulevard  
Bayside, NY 11361
- Affiliated Teaching Institutions**
- James J. Peters VA Medical Center**  
130 West Kingsbridge Road  
Bronx, NY 10468
  - NYC Health+Hospitals/Elmhurst**  
79-01 Broadway  
Queens, NY 11373
  - Mount Sinai-Union Square**  
10 Union Square East  
New York, NY 10003

## FACULTY NEWS: NEW APPOINTMENTS



**Anita Gupta, MD**  
Vice Chair for Professional Development, MSHS  
Director, Cornea and External Diseases, NYEE



**Meenakshi Gupta, MD**  
Director, Resident and Fellow Wellness, MSHS



**Mark Kupersmith, MD**  
Vice Chair for Translational Ophthalmology Research, MSHS



**Gennady Landa, MD**  
Director, Retina Service, NYEE



**Stephanie M. Llop Santiago, MD**  
Director, Uveitis and Ocular Immunology Fellowship Program, NYEE



**Louis R. Pasquale, MD, FARVO**  
Deputy Chair for Research, Department of Ophthalmology, ISMMS  
Director of Mount Sinai/NYEE Eye and Vision Research Institute, MSHS




**Harsha S. Reddy, MD**  
Director, Ophthalmology Residency Program, NYEE



**Richard B. Rosen, MD**  
System Chief, Retina Service, MSHS



**Kateki Vinod, MD**  
Director, Glaucoma Fellowship Program, NYEE



**Angie E. Wen, MD**  
Director, Cornea and External Diseases Fellowship Program, NYEE

## FACULTY NEWS: NEW RECRUITS

### > Cornea and External Diseases



**David Harris, MD**  
Residency, Ophthalmology, University of Kentucky College of Medicine Fellowship, Cornea and External Diseases, University of Kentucky College of Medicine



**Neha Shaik, MD**  
Residency, Ophthalmology, SUNY Downstate Medical Center Fellowship, Cornea, External Disease & Refractive Surgery, Bascom Palmer Eye Institute

### > Glaucoma



**Sze Wong, MD**  
Residency, Ophthalmology, Rutgers New Jersey Medical School Fellowship, Glaucoma, NYEE

## Icahn School of Medicine at Mount Sinai Departmental Leadership

**James C. Tsai, MD, MBA**  
President, NYEE  
System Chair, Department of Ophthalmology, MSHS

**Louis R. Pasquale, MD, FARVO**  
Site Chair, Department of Ophthalmology, MSH and MSQ  
Deputy Chair for Research, ISMMS  
Director, Mount Sinai/NYEE Eye and Vision Research Institute, MSHS

**Paul A. Sidoti, MD**  
Site Chair, Department of Ophthalmology, NYEE  
System Chief, Glaucoma, MSHS

**Douglas Fredrick, MD**  
Deputy Chair for Education, MSHS  
System Chief, Pediatric Ophthalmology and Strabismus, MSHS

**Richard B. Rosen, MD**  
Deputy Chair for Clinical Affairs, MSHS  
Vice Chair and Director of Ophthalmic Research, NYEE  
System Chief, Retina Service, MSHS

**Salvatore Loiacono, Jr., MPA**  
Deputy Chair for Finance and Administration, MSHS  
Vice President for Ophthalmology Services, NYEE

**Christopher T. Spina, MS**  
Senior Vice President and Chief Operating Officer, NYEE

**Tamiesha Frempong, MD, MPH**  
Vice Chair for Diversity and Inclusion, MSHS

**Anita Gupta, MD**  
Vice Chair for Professional Development, MSHS  
Director, Cornea and External Diseases, NYEE

**Mark Kupersmith, MD**  
Vice Chair, Translational Ophthalmology Research, MSHS  
System Chief, Neuro-Ophthalmology, MSHS

**Sandra K. Masur, PhD**  
Vice Chair for Academic Development and Mentoring, MSHS

**Paul S. Lee, MD**  
President, NYEE/MSH Department of Ophthalmology Alumni Associate Residency Program Director, MSH

## Residency and Fellowship Programs

**Harsha S. Reddy, MD**  
Director, Ophthalmology Residency Program, NYEE

**Tamiesha Frempong, MD, MPH**  
Director, Pediatric Ophthalmology Fellowship Program, NYEE

**Stephanie M. Llop Santiago, MD**  
Director, Uveitis and Ocular Immunology Fellowship Program, NYEE

**Richard B. Rosen, MD**  
Director, Vitreo-Retinal Fellowship Program, NYEE

**Kateki Vinod, MD**  
Director, Glaucoma Fellowship Program, NYEE

**Angie E. Wen, MD**  
Director, Cornea and External Diseases Fellowship Program, NYEE

**Medical Directors**  
**Avnish Deobhakta, MD**  
Medical Director, East 85th Street

**Robin N. Ginsburg, MD**  
Medical Director, East 102nd Street

**Gennady Landa, MD**  
Medical Director, Tribeca

**Kira Manuasis, MD**  
Medical Director, Midwood

**Paul A. Sidoti, MD**  
Medical Director, East 14th Street

**Angie E. Wen, MD**  
Medical Director, Columbus Circle

## Clinical Divisions at Mount Sinai Health System Faculty Practices

**Cornea, External Diseases, and Refractive Surgery**  
**Sumayya Ahmad, MD**  
**Priti Batta, MD**  
**Anita Gupta, MD**  
**David Harris, MD**  
**Kira Manuasis, MD**  
**Neha Shaik, MD**  
**Angie E. Wen, MD**

**Eye Trauma**  
**John Aljian, MD**  
**Ronald C. Gentile, MD**  
**Harsha S. Reddy, MD**

**Glaucoma**  
**Paul Sidoti, MD**  
System Chief, Glaucoma, MSHS

**Nisha Chadha, MD**  
**Donna Gagliuso, MD**  
**Tsontcho Ianchulev, MD**  
**Louis R. Pasquale, MD, FARVO**  
**Nathan Radcliffe, MD**  
**Robert Ritch, MD**  
**Tania Tai, MD**  
**James C. Tsai, MD, MBA**  
**Kateki Vinod, MD**  
**Sze Wong, MD**

**Neuro-Ophthalmology**  
**Mark Kupersmith, MD**  
System Chief, Neuro-Ophthalmology, MSHS

**Valerie Elmalem, MD**  
**Joel Mindel, MD**

**Ocular Oncology**  
**Paul Finger, MD**

**Ophthalmic Pathology**  
**Jodi Sassoon, MD**  
Site Chair, Pathology, NYEE

**Nada Farhat, MD**  
**Alan Friedman, MD**  
**Codrin Iacob, MD**

**Oculoplastic, Orbital and Reconstructive Surgery**  
**Robert Della Rocca, MD**  
System Chief, Oculoplastic, Orbital and Reconstructive Surgery, MSHS

**David A. Della Rocca, MD**  
**Monica Dweck, MD**  
**Valerie Elmalem, MD**  
**Harsha S. Reddy, MD**

## Pediatric Ophthalmology and Strabismus

**Douglas Fredrick, MD**  
System Chief, Pediatric Ophthalmology and Strabismus, MSHS

**Tamiesha Frempong, MD, MPH**  
**Edward Raab, MD**  
**Steven Rosenberg, MD**  
**Erin Walsh, MD**

**Primary Care Ophthalmology/Optomety**  
**Karen Henderl-Goldberg, MD**  
**Bessie Abraham, OD**  
**Jared Hayashi, OD**  
**Vanessa Hernandez, OD**  
**Elena Schmidt, OD**

**Retina**  
**Richard B. Rosen, MD**  
System Chief, Retina Service, MSHS

**Avnish Deobhakta, MD**  
**Robin Ginsburg, MD**  
**Meenakshi Gupta, MD**  
**Gennady Landa, MD**  
**Gareth Lema, MD, PhD**  
**R. Theodore Smith, MD, PhD**

**Uveitis and Ocular Immunology**  
**Stephanie M. Llop Santiago, MD**  
**Sophia Saleem, MD**

**Basic Science/Translational Research Faculty**  
**Yuen Ping Toco Chui, PhD**  
**Bo Chen, PhD**  
**R. Theodore Smith, MD, PhD**  
**Jose Mario Wolosin, PhD**

**Affiliated Leadership**  
**Paul Lee, MD**  
Chief of Ophthalmology, James J. Peters VA Medical Center

**Robert Fischer, MD**  
Director of Ophthalmology, Elmhurst Hospital

**Michelle Rhee, MD**  
Associate Director of Ophthalmology, Elmhurst Hospital

**ISMMS** - Icahn School of Medicine at Mount Sinai  
**NYEE** - New York Eye and Ear Infirmary of Mount Sinai  
**MSBI** - Mount Sinai Beth Israel  
**MSHS** - Mount Sinai Health System  
**MSH** - The Mount Sinai Hospital  
**MSQ** - Mount Sinai Queens



## Current Residents and Fellows

### NYEE Residents

**PGY-4**  
**Masako Chen, MD**  
**Rachel Lee, MD**  
**Jonathan Lo, MD**  
**Neesurg Mehta, MD**  
**Thomas Quehl, MD**  
**Manan Sampat, MD**  
**Cissy Yang, MD**

### PGY-3

**Michael Chua, MD**  
**Karen Hu, MD**  
**Mary Labowsky, MD**  
**Kelly Lee, MD**

**David MacPherson, MD**  
**Duaa Sharfi, MD**  
**Daniel Wang, MD**

### PGY-2

**Julia Fallon, MD**  
**Roxanne Lee, MD**  
**Sarah McCord, MD**  
**Shravan Savant, MD**  
**Young Seol, MD**  
**Tommaso Vagaggini, MD**  
**Bella Wolf, MD**

### NYEE Fellows

**Laiyin Ma, MD (Cornea)**

**Jane Song, MD (Glaucoma)**  
**Rebecca Weiss, MD (Pediatrics)**  
**Richard Kaplan, MD (Retina)**  
**Brittany Powell, MD (Retina)**  
**Alexander Pinhas, MD (Retina)**  
**Vincent Sun, MD (Retina)**  
**Palak Majmudar, MD (Uveitis)**

### MSH Residents

**PGY-4**  
**Colin Anderson, MD**  
**Sarah Avila, MD**  
**Joel Pakett, MD**  
**Carl Wilkins, MD**

### PGY-3

**Cesar Alfaro, MD**  
**Kirolos Ibrahim, MD**  
**Ekta Patel, MD**  
**Ethan Sobol, MD**

### PGY-2

**Rupak Bhuyan, MD**  
**Karina Esquenazi, MD**  
**Susel Oropesa, MD**  
**Kevin Wu, MD**

### MSH Fellow

**Michelle Packles, MD (Glaucoma)**

Celebrating  
**200**  
YEARS  
1820 - 2020



New York  
Eye and Ear  
Infirmary of  
**Mount  
Sinai**

## SAVE THE DATE

NYEE Celebrates Its

# 200th Anniversary

Join faculty, alumni, and friends of NYEE for a two-day celebration of our 200-year legacy of leadership, innovation, and excellence in patient care.

## October 15, 2020

Bicentennial Gala Fundraiser

The Plaza Hotel  
768 Fifth Avenue  
New York, NY

## October 16, 2020

Transformational Ophthalmology 2020:  
Envisioning Our Third Century

New York Academy of Medicine  
1216 Fifth Avenue  
New York, NY

For more information and tickets  
visit: [www.nyee.edu/200years](http://www.nyee.edu/200years)